



# ULTRALYD DOPPLER VED PORTAL HYPERTENSJON OG AV ANDRE ABDOMINALKAR

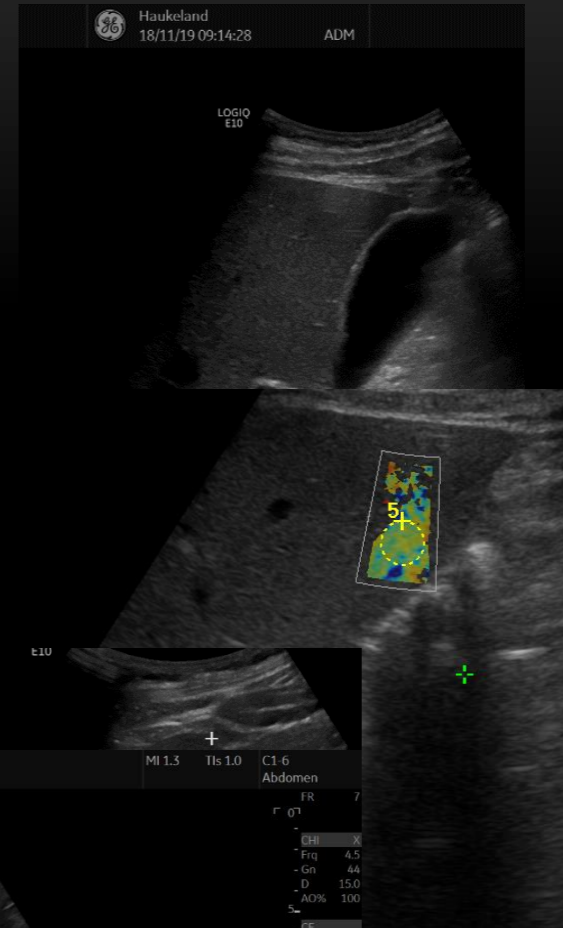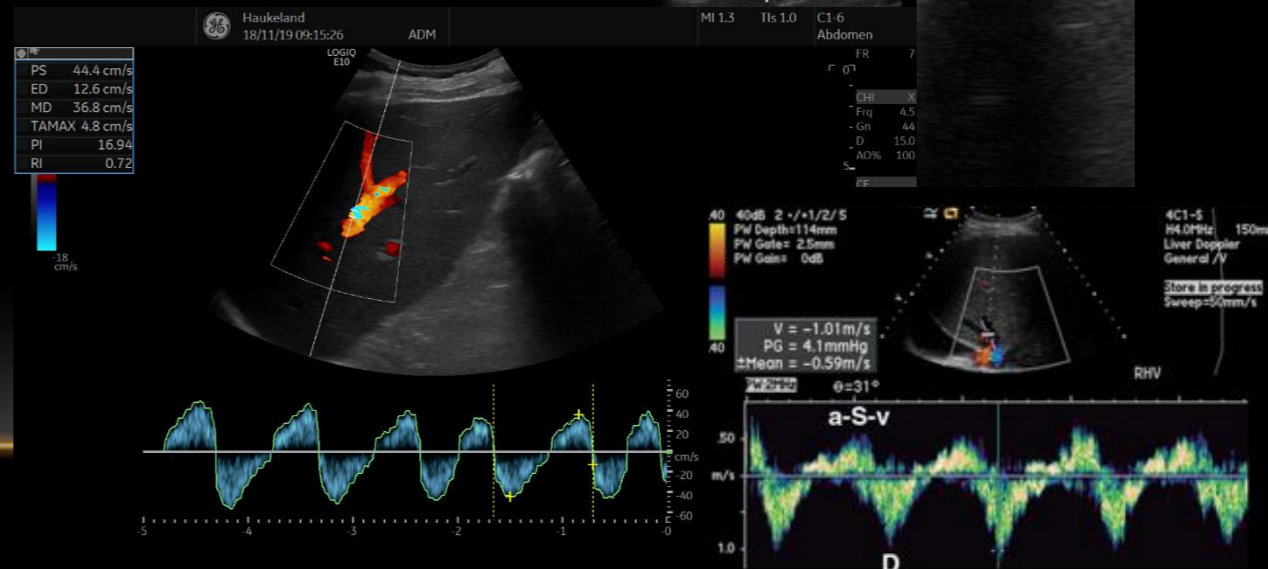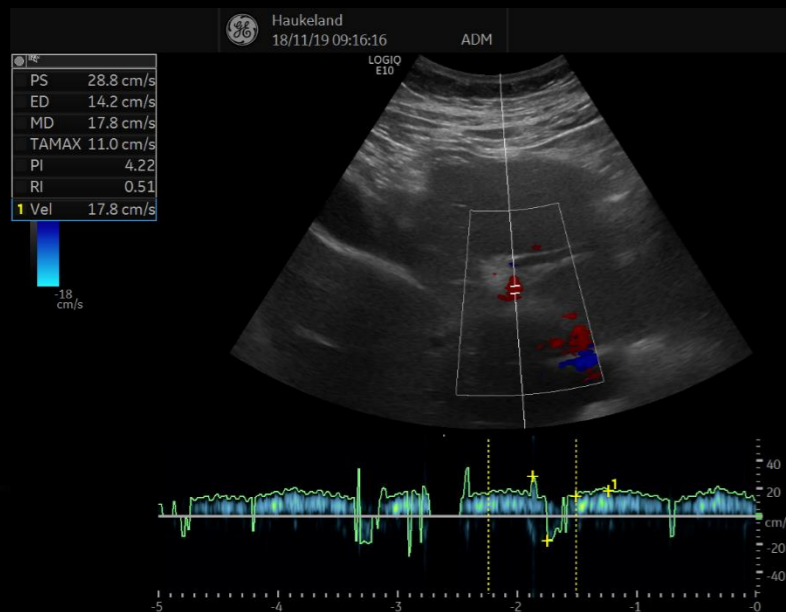
Flow-fysiologi og bølgemønster relatert til klinikk

Trond Engjom, PhD, Seksjonsoverlege  
Seksjon for fordøyelsessjukdommer, HUS



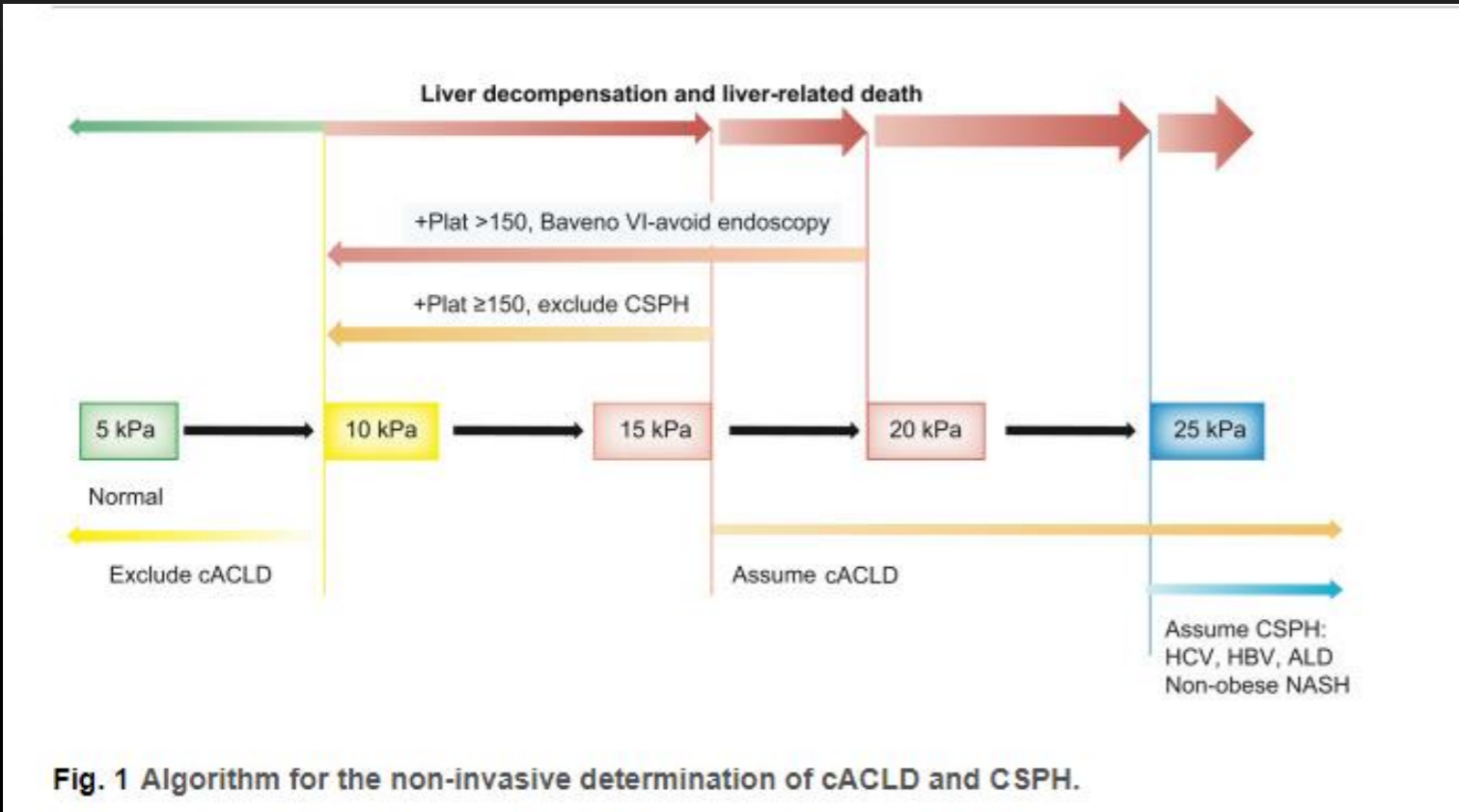
# MANN, 74 MED ØKTE LEVERTRANSAMINASER OG LETT TROMBOCYTOPENI

- Kontinentalt alkoholforbruk
- Ikke annen leversykdom
- Atrieflimmer og lett aktivitetsdyspnoe.
- Er det primær leversykdom?





# TRENGER VI DOPPLER AV LEVERKAR NÅR VI HAR ELASTOGRAFI?



Post-treatment LSM & PLT	CSPH/ Varices/ Decompensation	Management
<b>Consistent improvement:</b> LSM < 12kPa & PLT > 150G/L	CSPH excluded (sensitivity: 99.2%) No risk of hepatic decompensation	Discharge from PH surveillance, if no co-factors ! Continue HCC surveillance !
LSM < 20kPa & PLT > 150G/L	High-risk varices ruled-out Low prevalence of CSPH Low risk of hepatic decompensation	No need for screening endoscopy
NSBB-therapy & LSM < 25kPa	Unknown	Repeat endoscopy & discontinue carvedilol (NSBB), if no varices
NSBB-therapy & LSM ≥ 25kPa	CSPH ruled-in (specificity: 93.6%)	Continue carvedilol (NSBB) treatment

Portal Hypertension VII  
Proceedings of the 7<sup>th</sup> Baveno Consensus Workshop: Personalized Care in Portal Hypertension

- Er elastografikvaliteten alltid god nok? – Flere ben å stå på i vurd av portal hypertensjon
- Hva med periportal sykdom?
- Differensialdiagnostikk mot leverstuvning
- Lever/portvenetromboseproblematikk? VOD?
- Om å ha kontroll på leverarterien



# DOPPLER AV ABDOMINALKAR

- Dopplerultral lyd er beste modalitet for å vurdere flow i leverkar
  - Leverarterie
  - Levervener
  - Portvener
  - (TIPS)
- Gir også informasjon om flow i store abdominalkar ved mistanke om mesenteriell angina.
  - Arteria mesenterica superior/ truncus coeliacus
- Volumvurdering ved hjelp av cava



# HVA TRENGER VI Å KUNNE?

- Enkel flow fysiologi
- Enkelt om doppler og dopplerbegreper
- Gjenkjenne et begrenset antall normale bølgeformer og patologiske bølgeformer koblet til kliniske syndromer

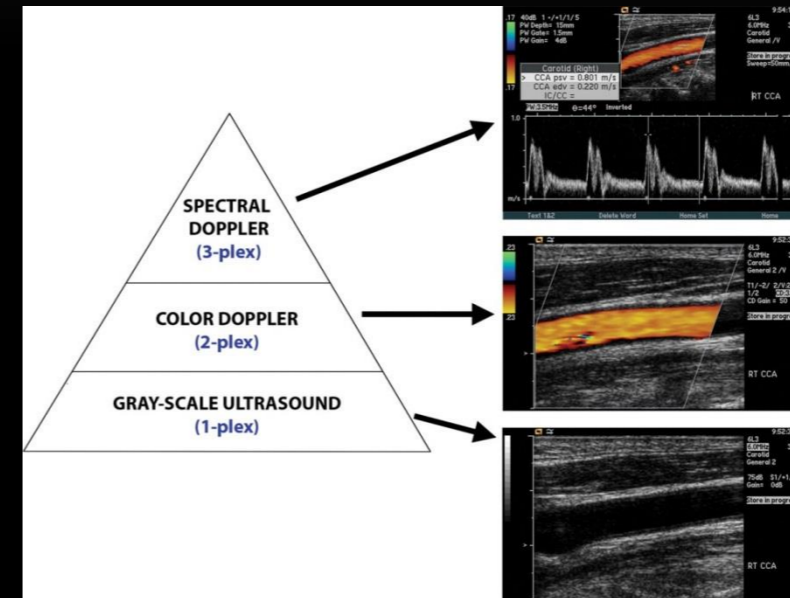
Christian Johann Doppler (1803–1853)  
(Østerrike)





# DOPPLER NOMENKLATUR

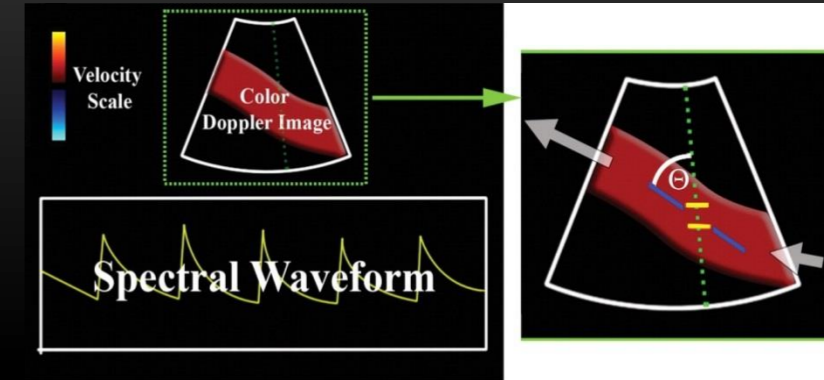
- Tre dopplernivåer
  - B Mode
  - Farge Doppler
  - Pulset doppler/ spectral doppler bølge







## OM VINKELN: $\theta$ , $<60^\circ$

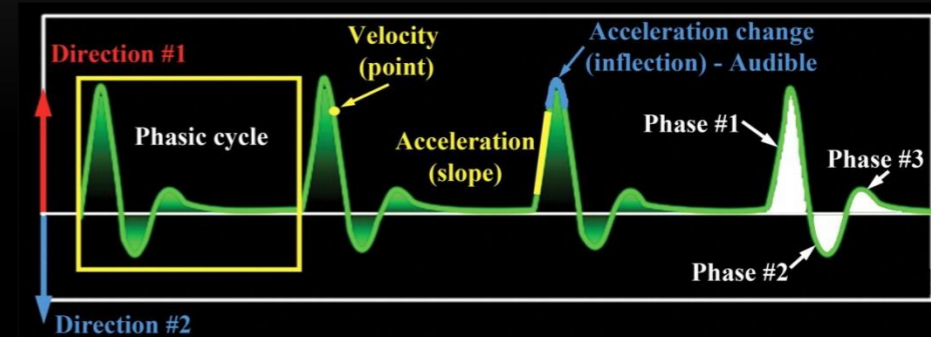


- $V = (DF)(C) / 2(Ft)(\cos\theta)$
- $\theta$  øker fra  $60^\circ$  til  $90^\circ$ ,  $\cos\theta$  reduseres fra 0.5 to 0.
- Små endringer i probeplassing gir store utslag for hastighetsmåling og målingene er ikke lenger reproducerbare.



# KOMPONENTER I SPEKTRALDOPPLERBØLGEN

- Retning (Over/ under baseline)
- Hastighet (Avstand fra baseline)
- Akselerasjon (Stigning)
- Endring i akselerasjon (Knekkpunkter)







# FLOW RETNING

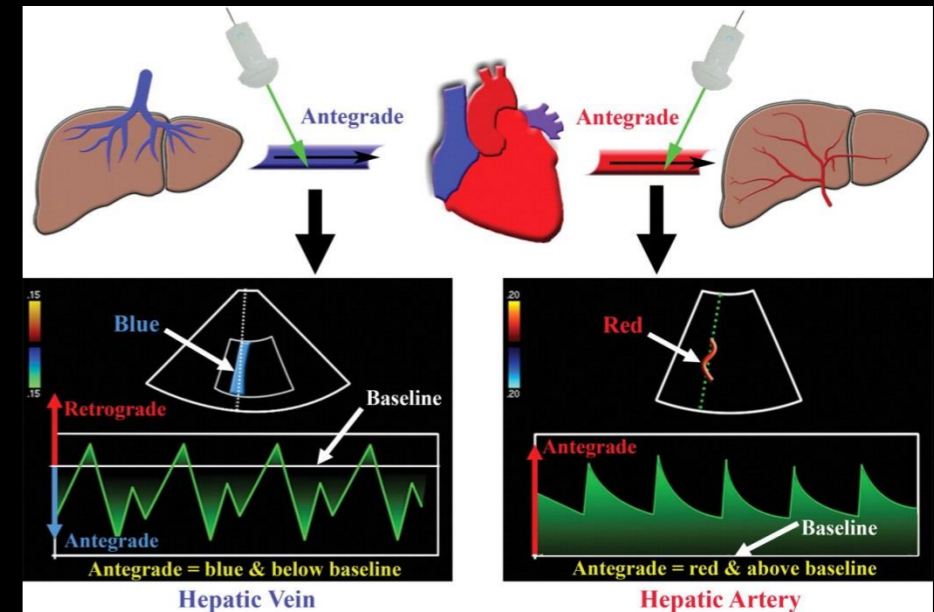
## Farge:

- Mot transducer: Rød/ positiv
- Fra transducer: Blå/ negativ

## Forhold til forventet flowretning:

- Antegrad: Som forventet
- Retrograd: Mot forventet

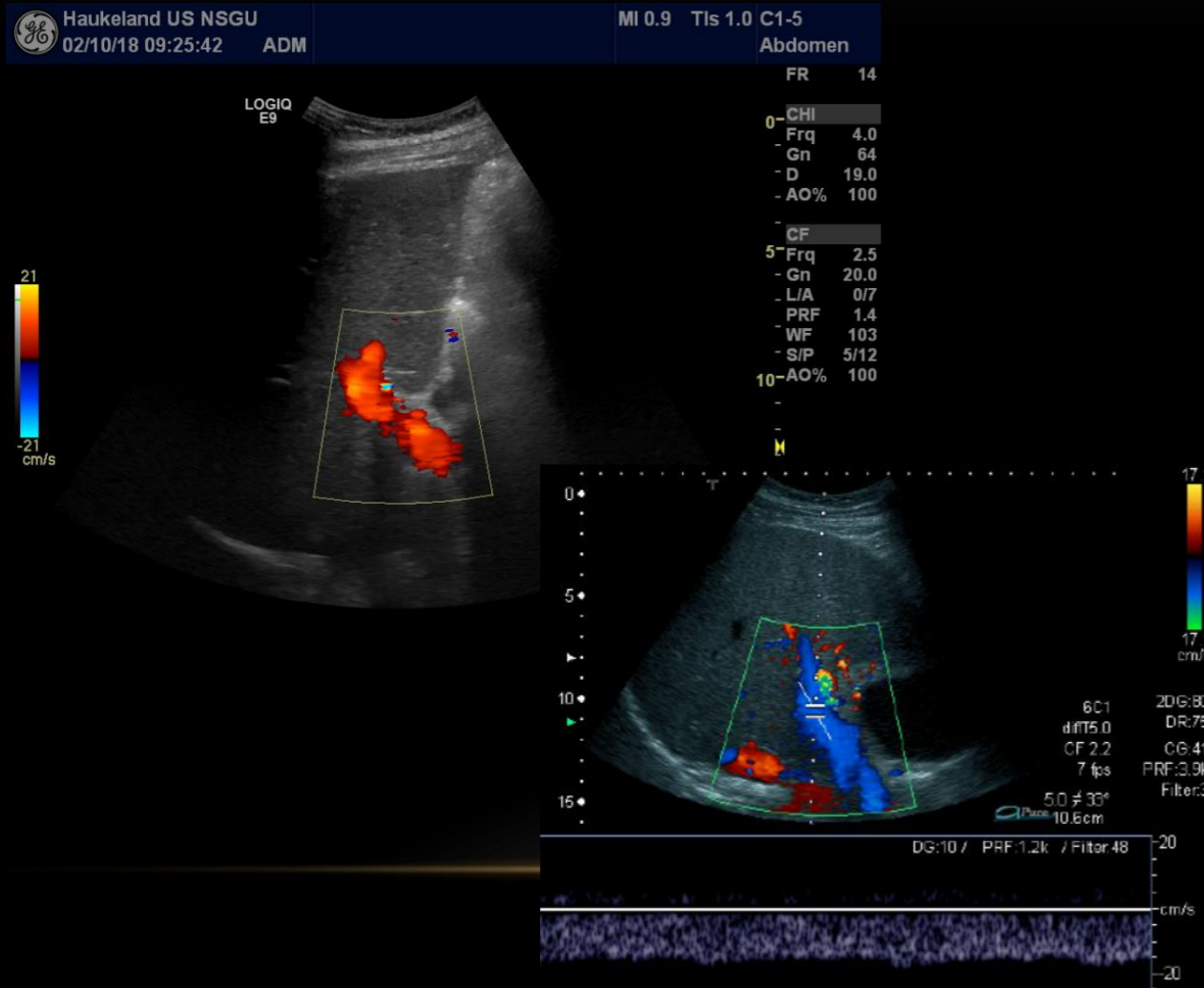
Antegrad kan være både blå og rød



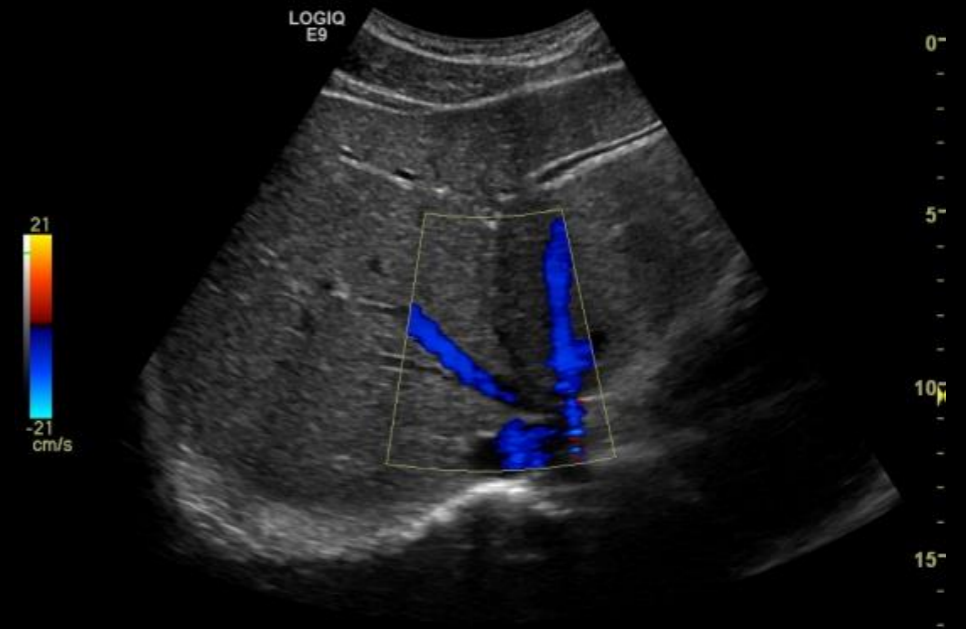


# ENKEL UTNYTTELSE AV DOPPLER RETNING (INVERTERT PORTVENEFLOW)

Portal vein: Red



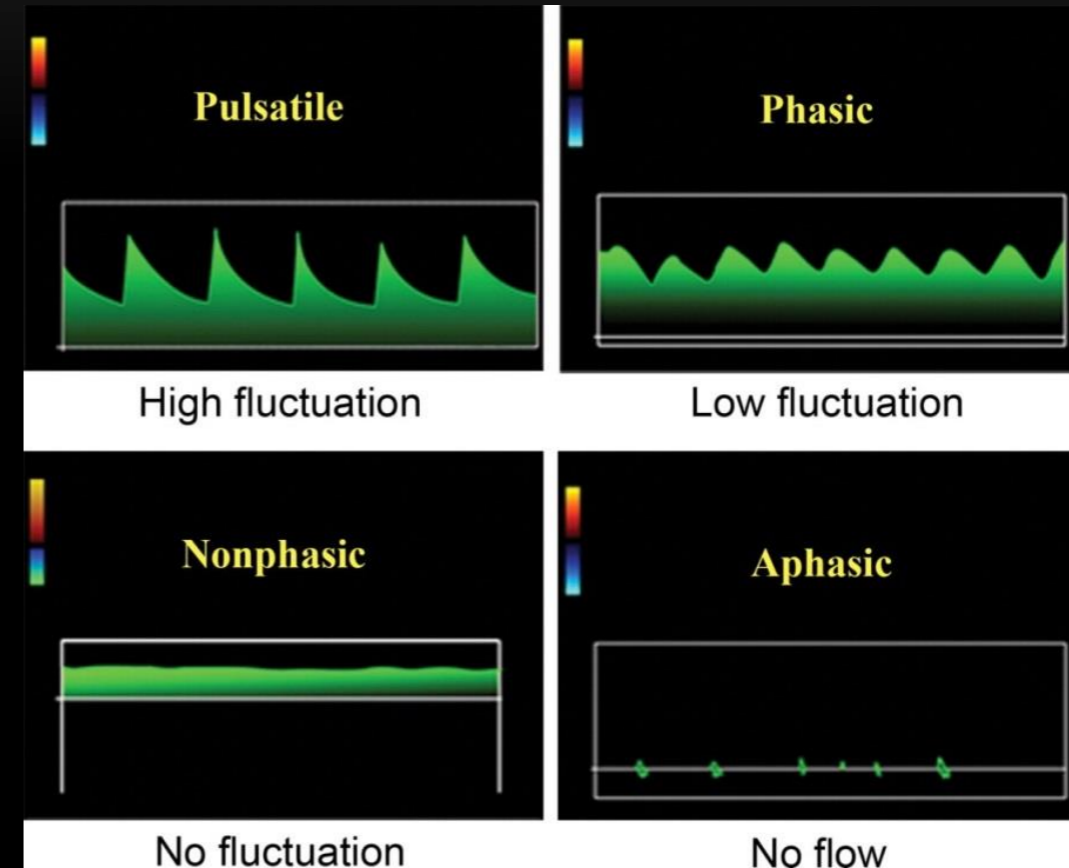
Liver veins: Blue





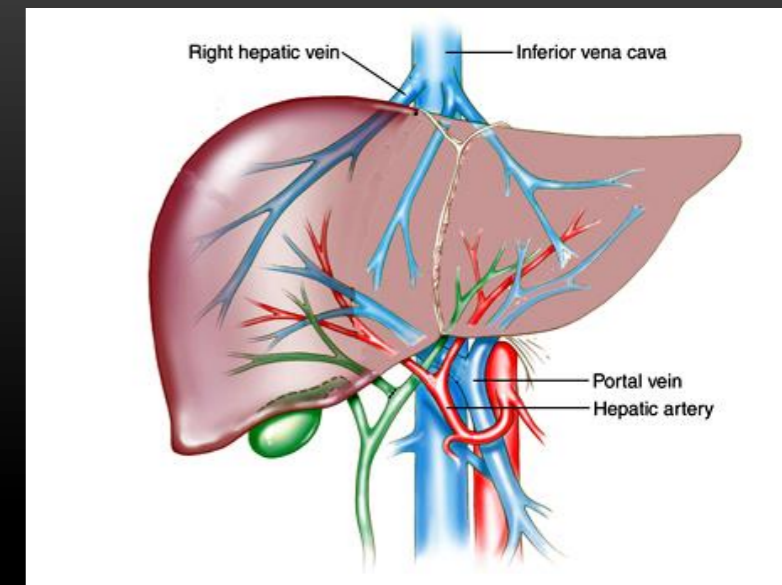
# FLOW FASITET ELLER PULSATILITET

- Fasisk (Syklisk): Regelmessige akselerasjonsendringer
- Pulsatil: Rask stigning og stor vertikal avstand mellom topp og bunn.
- Nonfasisk: Flow, men ingen akselerasjonsendringer
- Afasisk: Ingen flow.





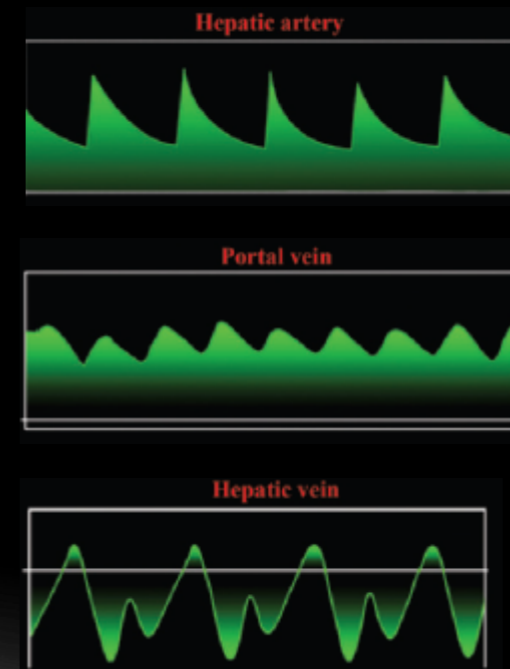
# TRE LEVERKAR- NORMALFUNN



Signaturen avhenger av

- anatomisk position i sirkulasjon
  - Arteriell (Leverarterie)
  - Venøs (Levervene)
  - Portal venøs (Portvene)
- Sykliske trykkvariasjoner generert av hjerteaktivitet

Memorer normalfunn





# LEVER ARTERIE

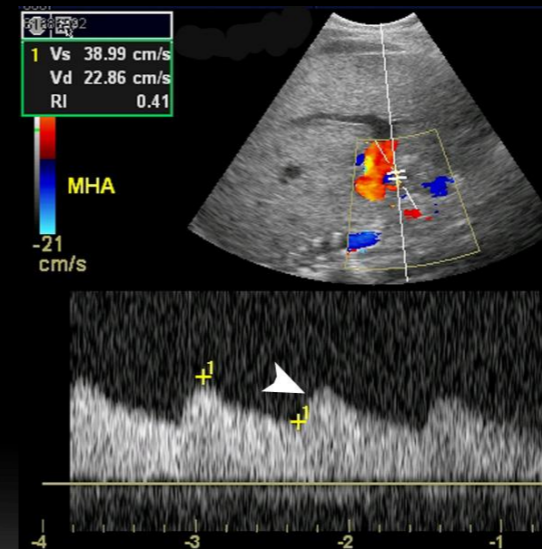
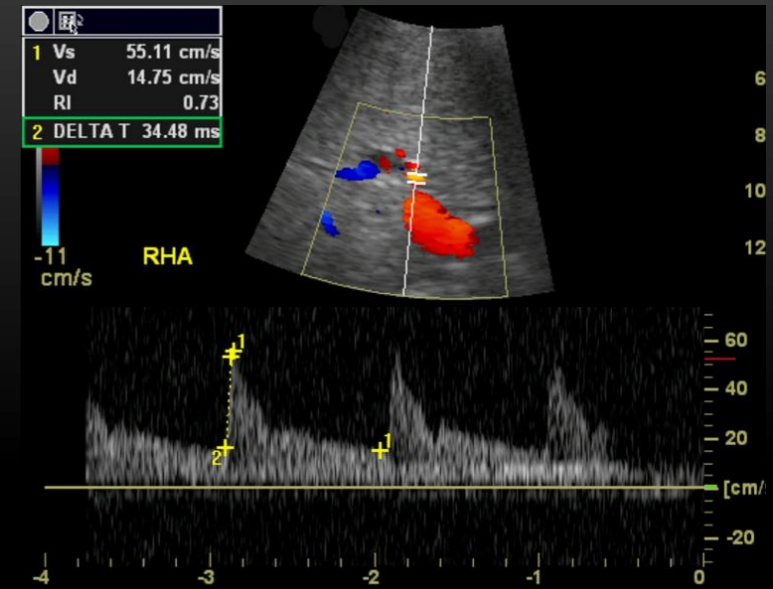
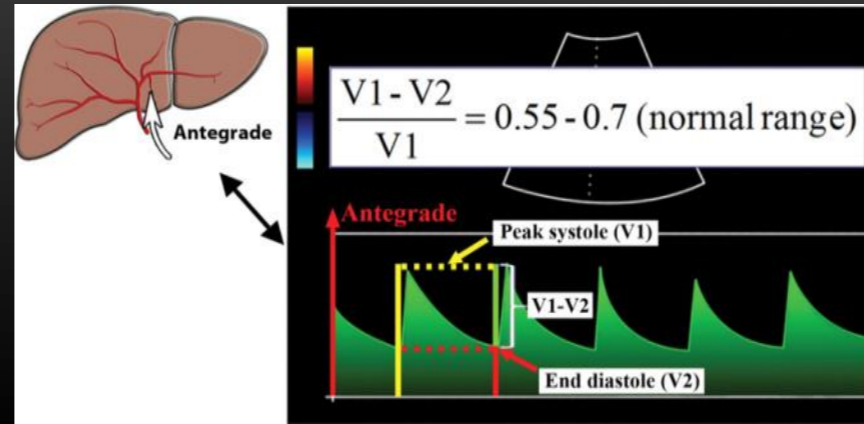
- Parallellt til sentral portvene.
- Alltid lav-resistens
- Normalverdier: RI 0.55–0.81

- **Høy RI**

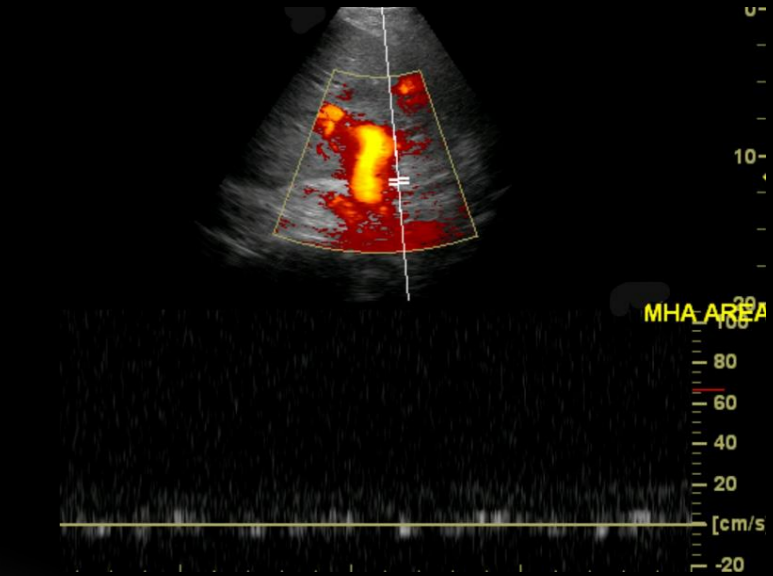
- Ikke spesifikt (Postprandialt? Høy alder? Diffus mikrovasc. sykdom?)

- **Lav RI (patologisk)**

- proximal stenose
- Distal vaskulær shunting



Tardus-parvus: poststenostisk

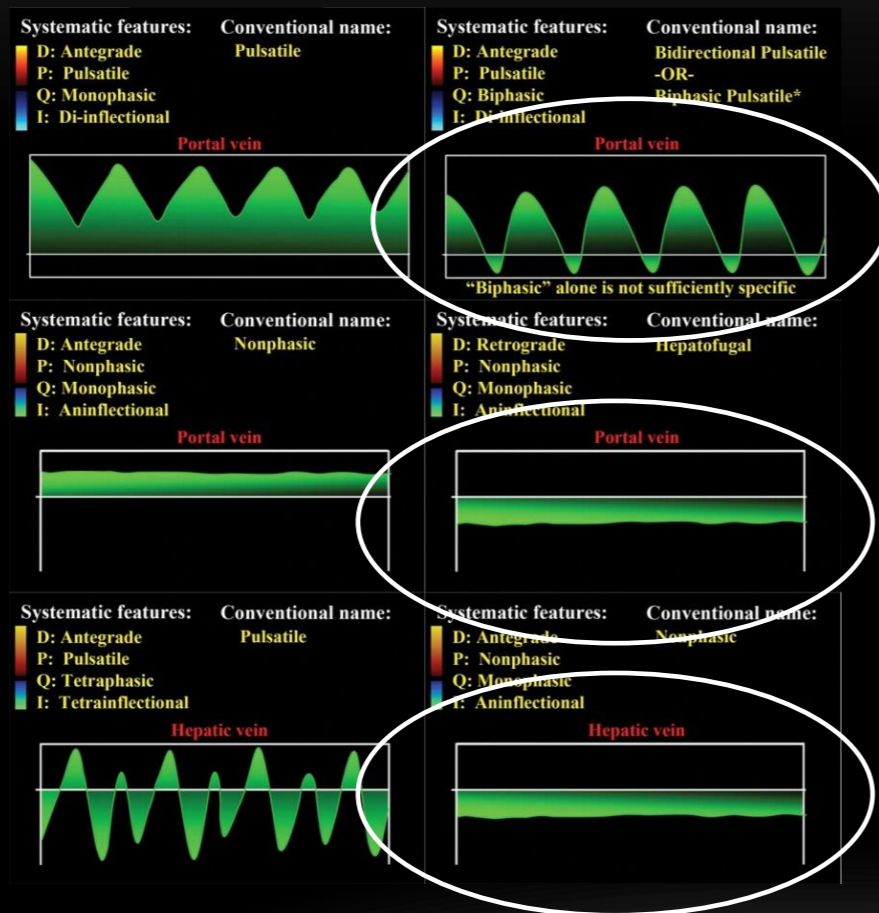


Trombose





# LEVER OG PORTVENER: NORMALT VS PATOLOGISK



Hø hjertesvikt/ TI

Alvorlig portalhypertensjon med reversert flow

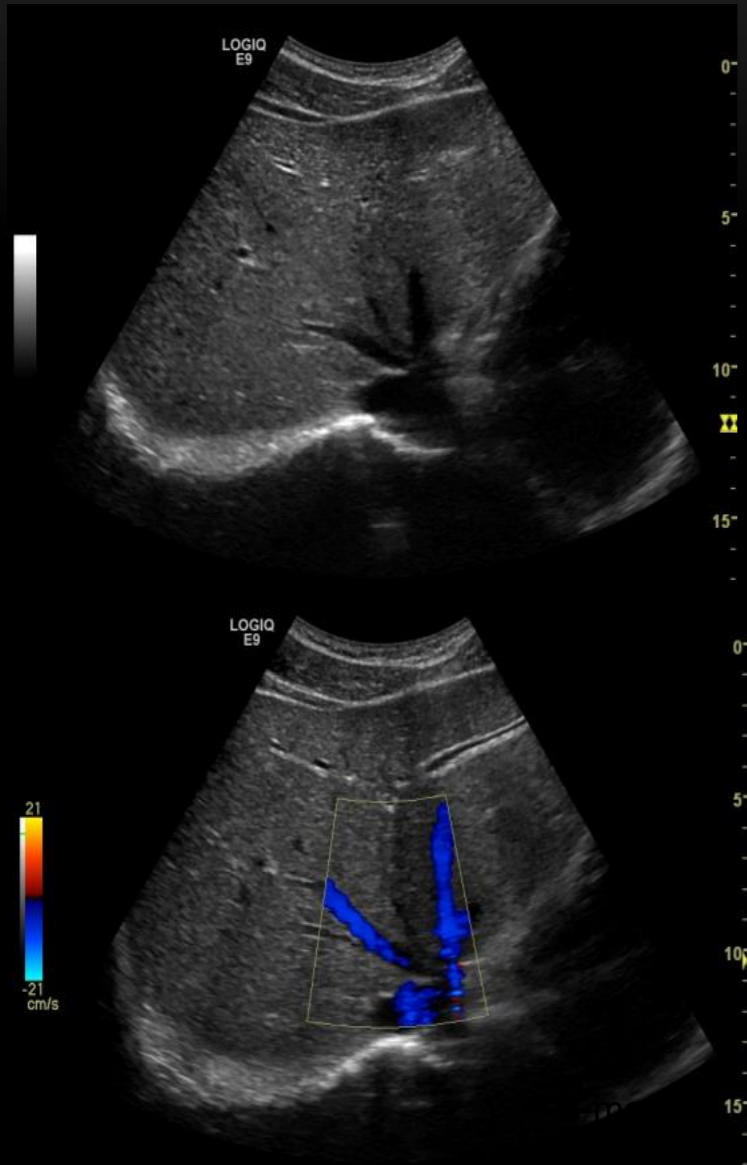
Alvorlig portalhypertensjon



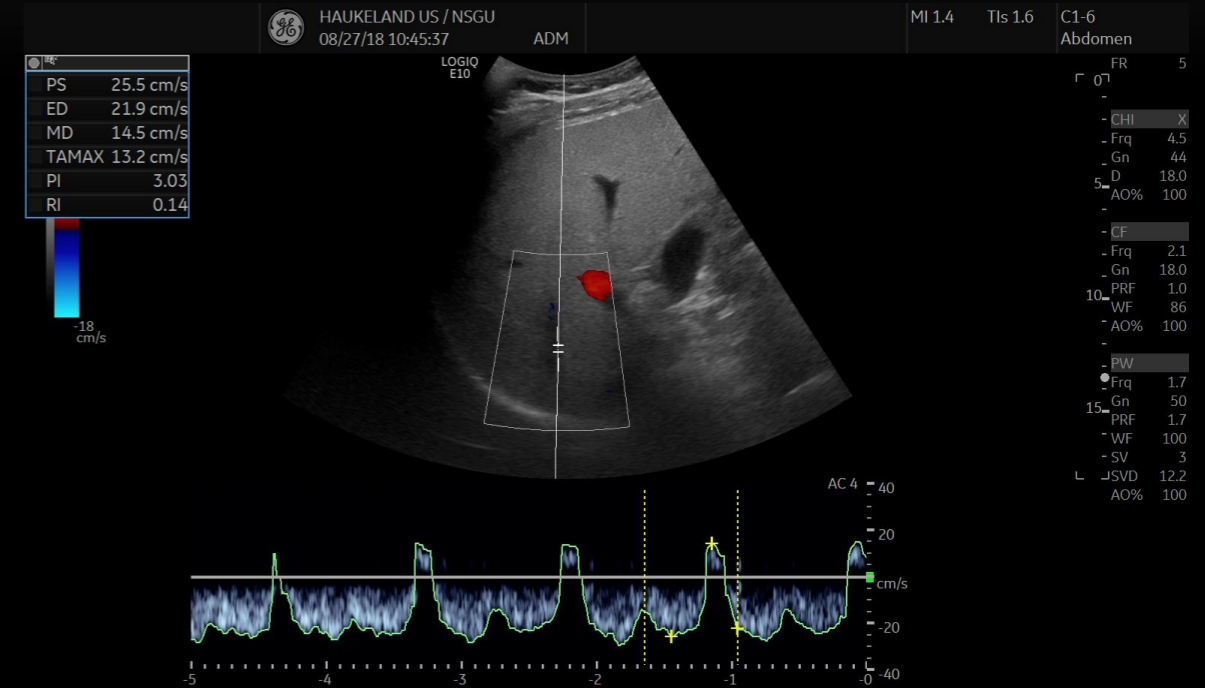


# LEVERVENER

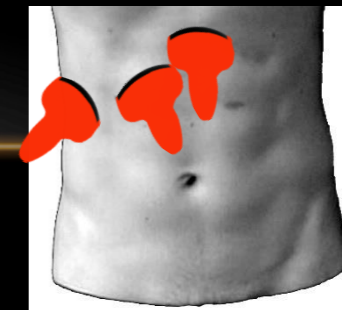
Dominerende flow mot hilus (Blå)  
trifasisk (tetrainflectional)



Color Doppler  
Blå=bort fra (Mot hilus)



Pulsa Doppler





# HVORDAN FORSTÅ LEVERVENEKURVEN

1. Flyter mot hjertet, dominerende antegrad og bort fra transducer (Blå)
2. Trykkforandringer i hø atrium overføres direkte til levervenene.
  - HAP↑: Bølge opp
  - HAP↓: Bølge ned

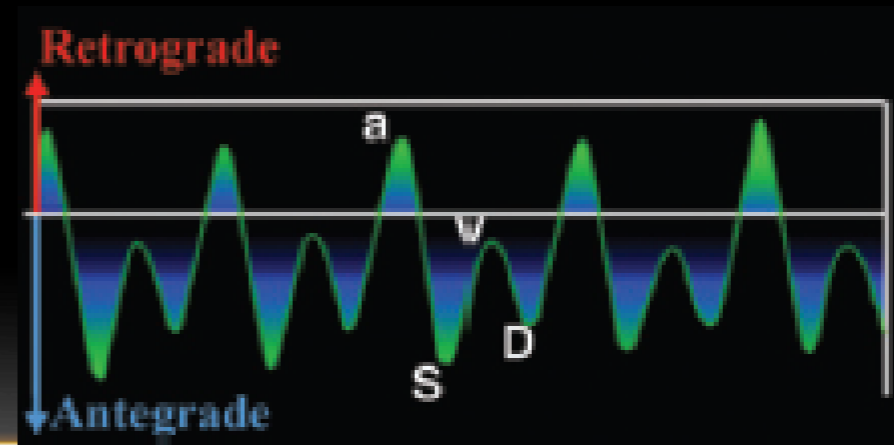
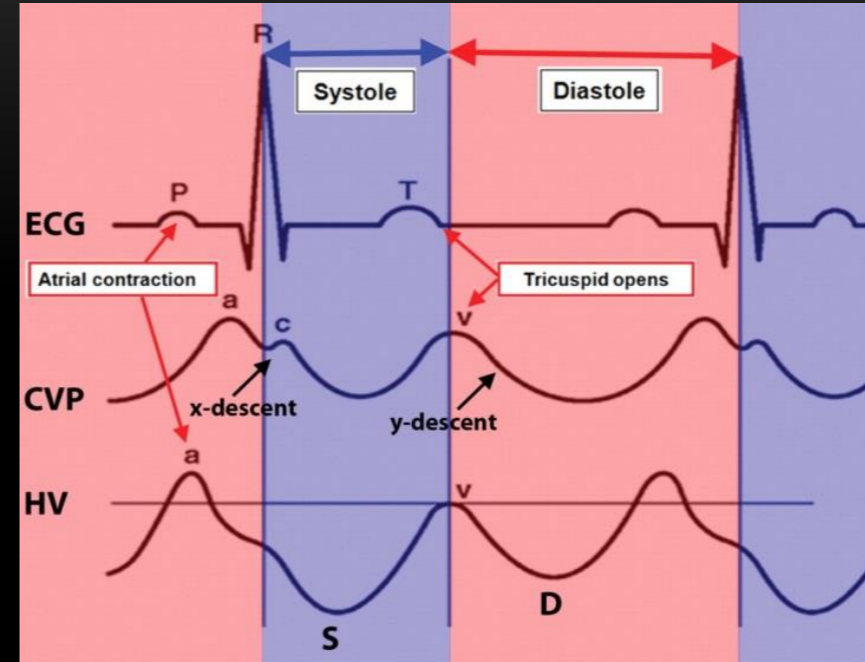
3. **A bølge:** Atriebølge

**S bølge:** Sept bølge

Neg trykk som følge av systolisk kontraksjon i AV septum

**V bølge:** tricuspidalklaff åpner

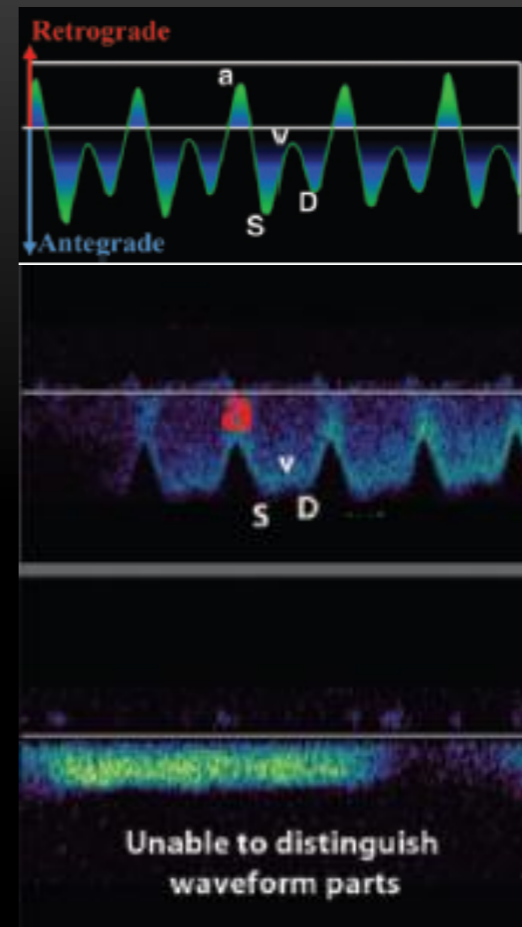**D bølge:** Maks tidlig diastolisk fylling





# PORTAL HYPERTENSJON: REDUSERT FASITET/ SPECTRAL BROADENING

- Undersøkes ved lett inspiratorisk pustestopp (Valsalva kan gi afasitet)
- Ved cirrhose
  - Levervevet mindre ettergivelig
  - Vene komprimeres.
  - Fri overføring av HA trykk hindres.
  - Redusert fasitet



Cirrhosis
Hepatic vein thrombosis (Budd-Chiari syndrome)
Hepatic veno-occlusive disease
Hepatic venous outflow obstruction from any cause

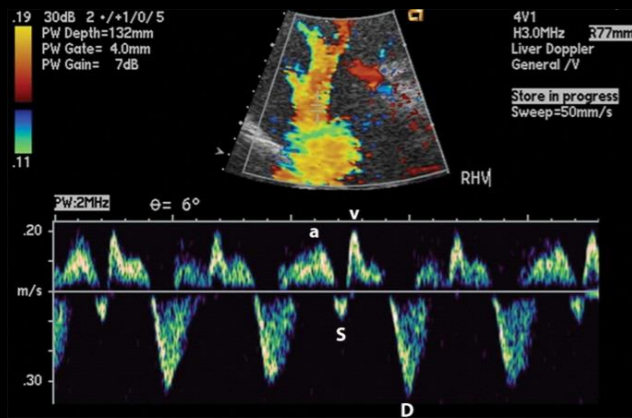
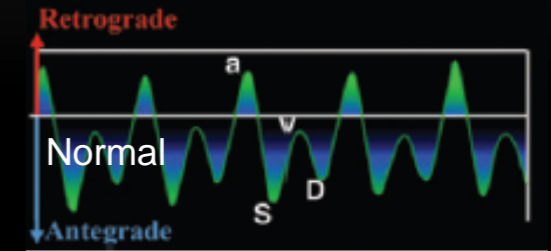


# TI ELLER HØYRE HJERTESVIKT (PULSATILT LEVERVENESIGNAL)

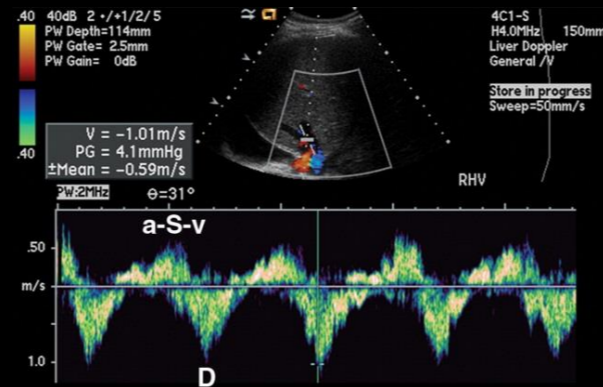
- Både antegrad og retrograd flow er dramatisk øket
  - Tricuspidalinsuff
  - Høyre hjertesvikt

Table 6  
Causes of Pulsatile Hepatic Venous Waveform

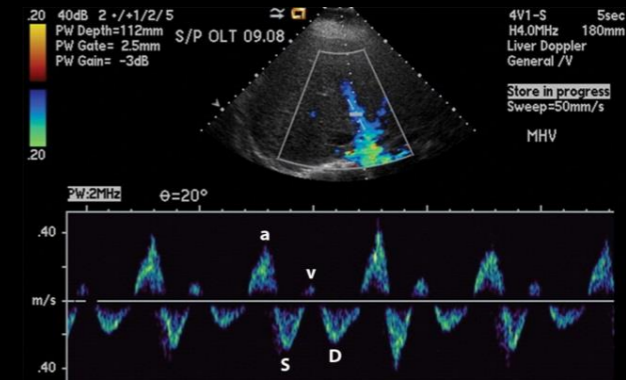
Tricuspid regurgitation
Decreased or reversed S wave
Tall a and v waves
Right-sided CHF
Maintained S wave/D wave relationship
Tall a and v waves



Mild TI  
a>S



Alvorlig TI  
Retrograd S: a-S-v bølge



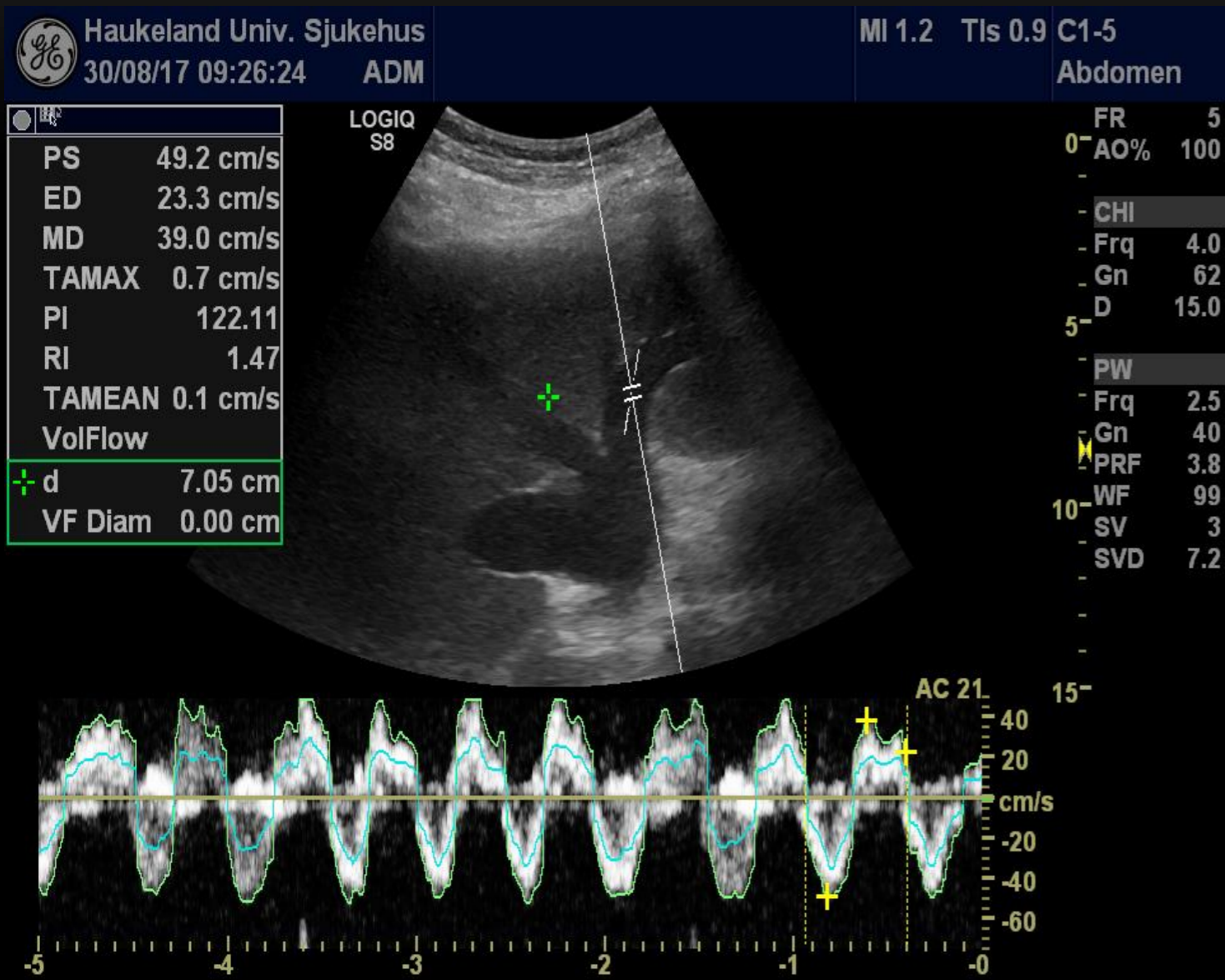
Høy hjertesvikt uten TI  
Høy a og v, S>D (Som normalt)



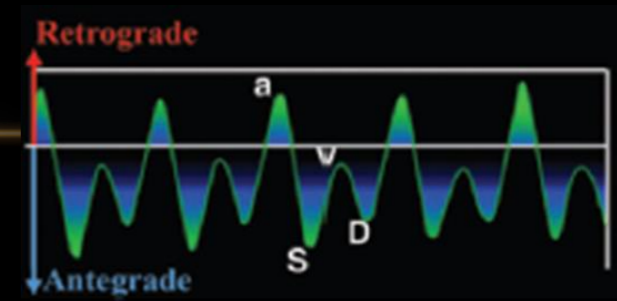


# Leverstuvning

## FETTLEVER



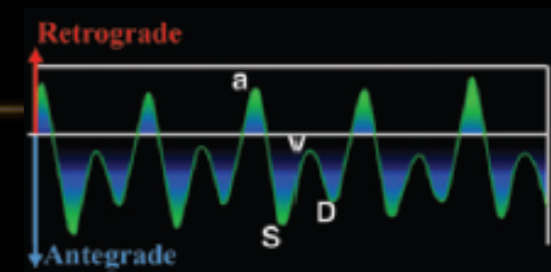
Leverstuvning og alvorlig TI pga høyresvikt





# LÆRINGSPUNKTER LEVERVENER

- Dominerende antegrad: Mot hilus, blå
- **Red fasitet:** Cirrhose/ portal HT: a-bølge vandrer nedover til fasen ikke lenger kan skilles.
- **Pulsatilitet:** Høyresvikt (A øker) eller TI (S minker/ reverseres)
- Afasitet: Budd-chiari, vene-okklusjon

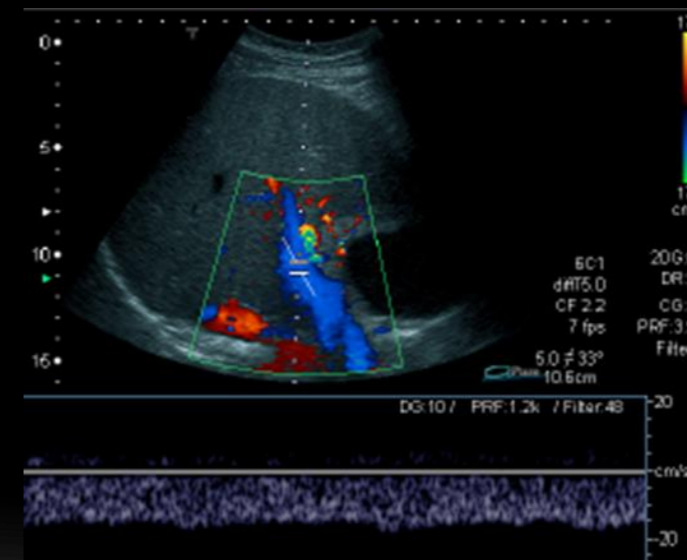
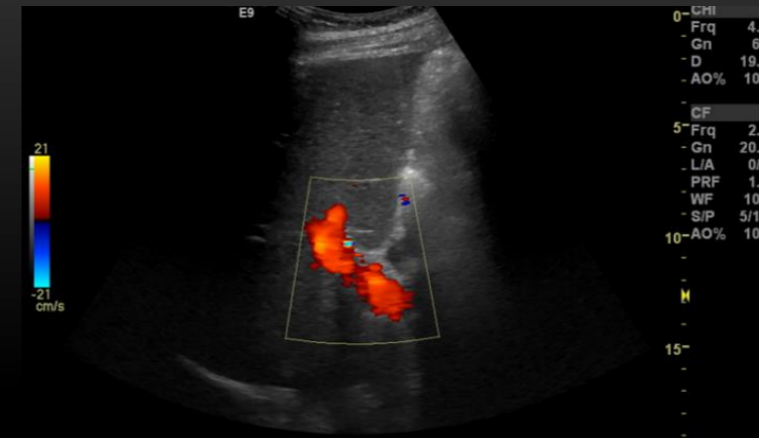






# PORTVENE

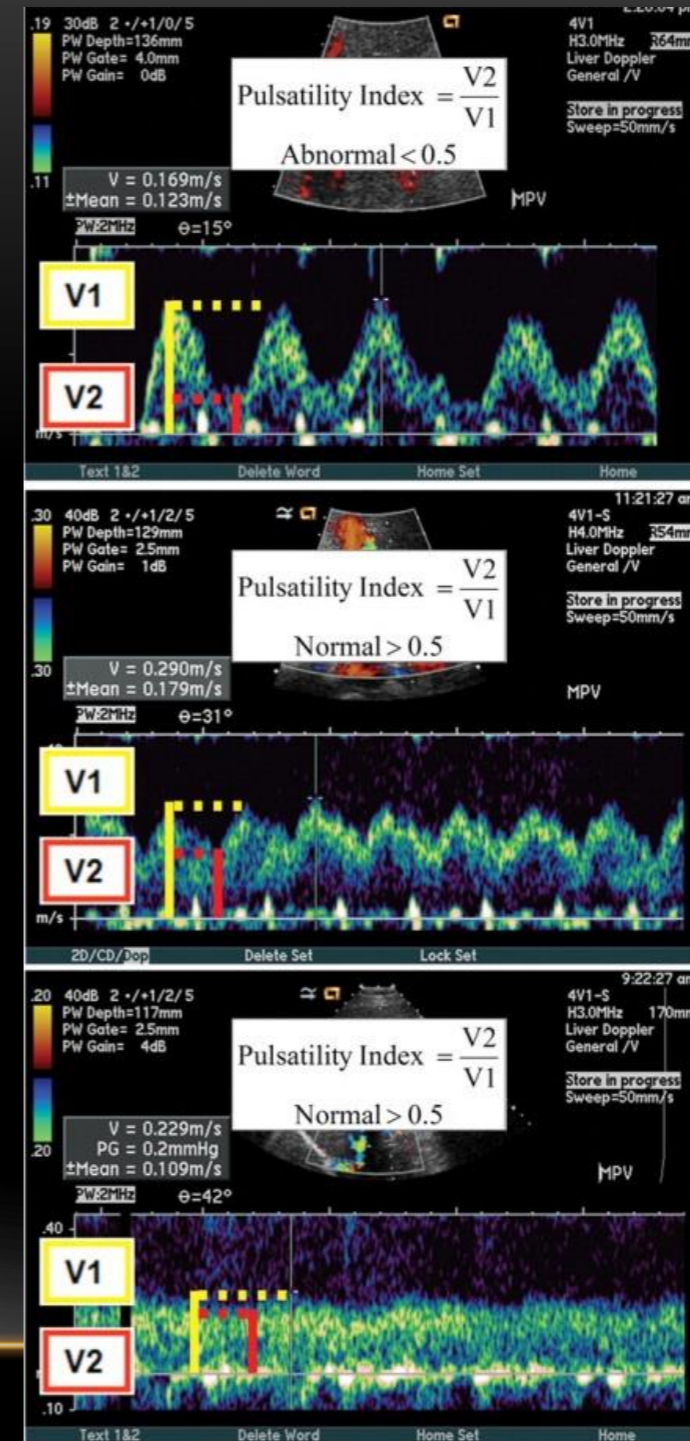
- Mot kapsel: Rød
- Variasjon kommer fra levervene via sinusoider
- Flow hastighet lav (16–40 cm/sec) sammenlignet med leverarterie





# VURDERE PORTVENE

- Flowretning (antegrad/ rød)
- Portvene-makshastighet (Normalt 16–40 cm/sec)
- Pulsalitetsindex (Normalt >0,5)
- Patologiske funn
  - Redusert flowhastighet
  - Avflating
  - Reversering
  - Portvenediameter: Normal <13-15mm)
  - Pulsatilitet?

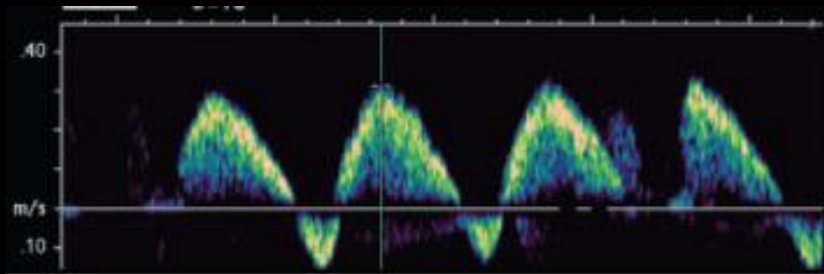
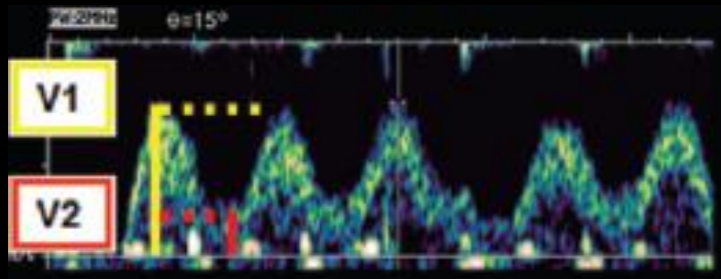




# PULSATIL ELLER REDUSERT FASITET

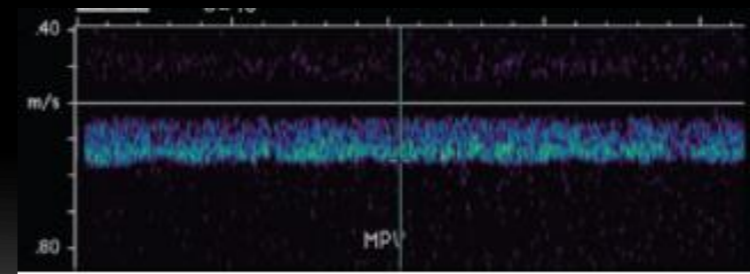
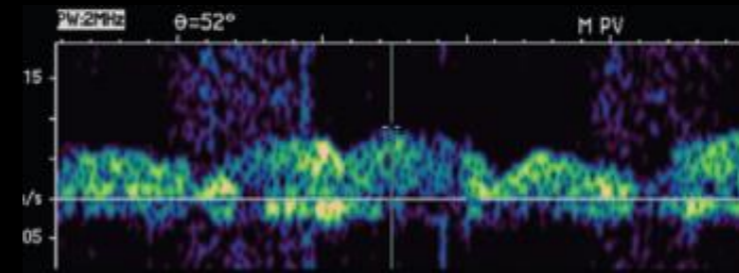
**Table 8**  
Causes of Pulsatile Portal Venous Waveform

Tricuspid regurgitation  
Right-sided CHF  
Cirrhosis with vascular arterioportal shunting  
Hereditary hemorrhagic telangiectasia–arteriovenous fistulas



**Table 9**  
Findings That Are Diagnostic for Portal Hypertension

Low portal venous velocity (<16 cm/sec)  
Hepatofugal portal venous flow  
Portosystemic shunts (including a recanalized umbilical vein)  
Dilated portal vein

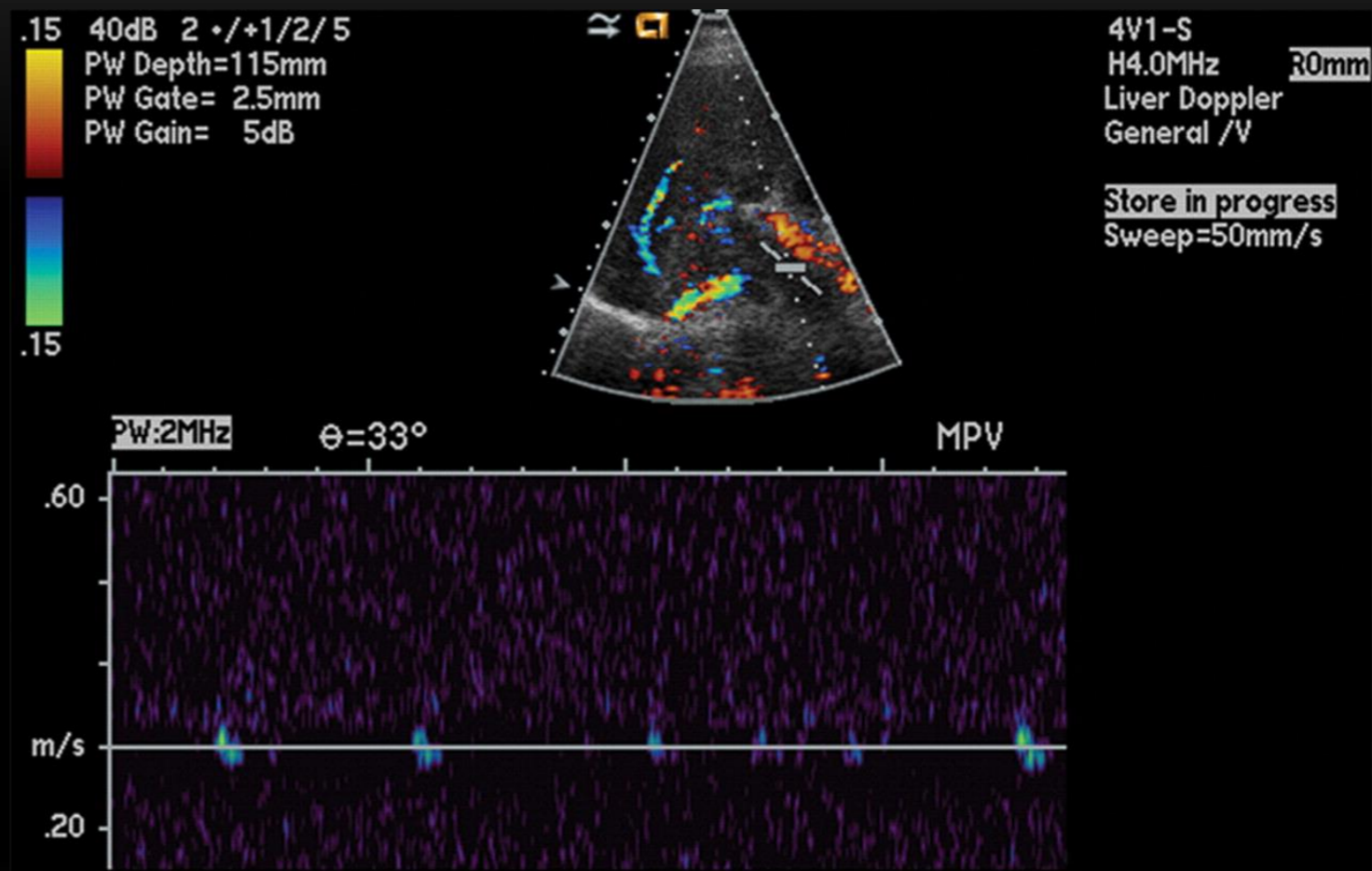




# FRAVÆR AV PORTVENEFLOW

Table 10  
Causes of Absent Portal Venous Flow

- Stagnant flow (severe portal hypertension)
- Portal vein thrombosis (bland thrombus)
- Tumor invasion

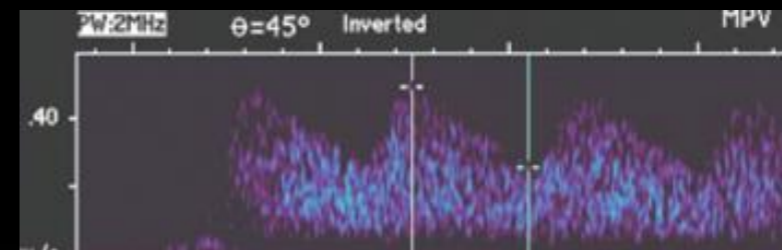
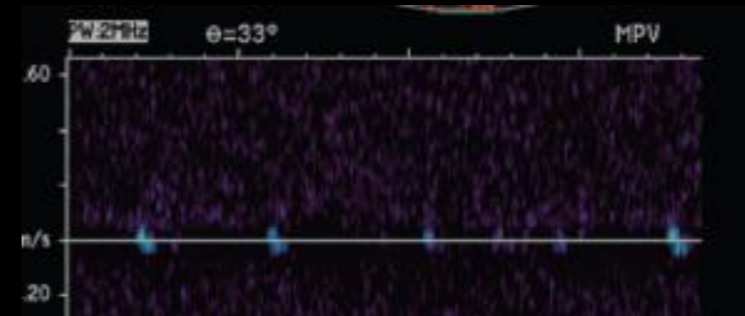
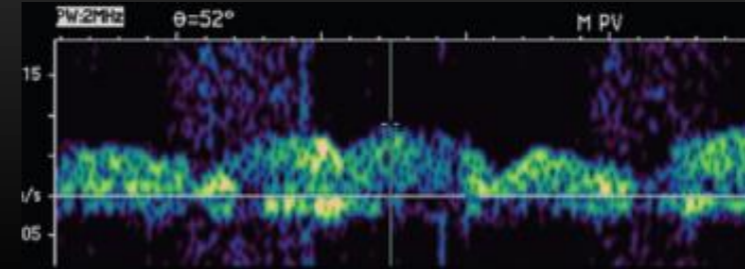






# PORTVENETROMBOSE

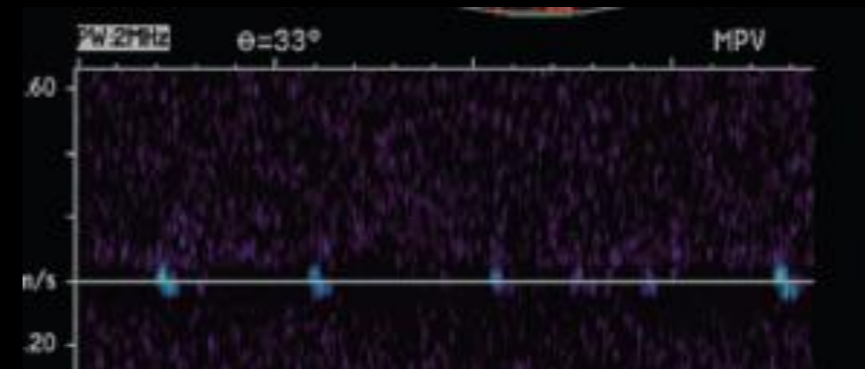
- Langsom flow: Prehepatisk trombose
- Ingen flow: Afasisk, komplett trombose, pre/intrahepatisk
- Pulsatil flow: Inkomplett tumortrombose





# LÆRINGSPUNKTER PORTVENE

- Flowretning (antegrad/ rød)
- Portvenehastighet  $>13\text{cm/s}$
- Portvenediameter: Normal  $<13\text{-}15\text{mm}$ )
  
- Patologiske funn
  - Redusert flowhastighet
  - Avflating
  - Reversering
  - Pulsatilitet?







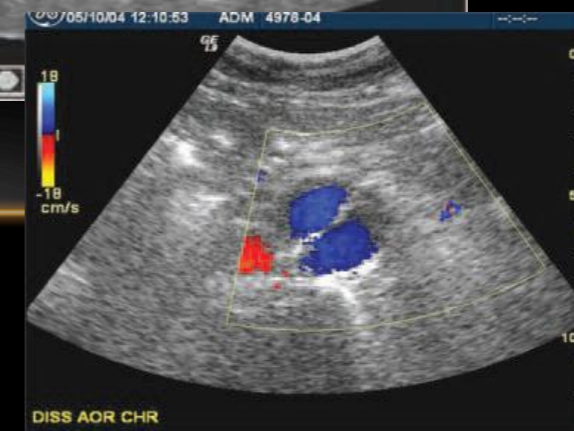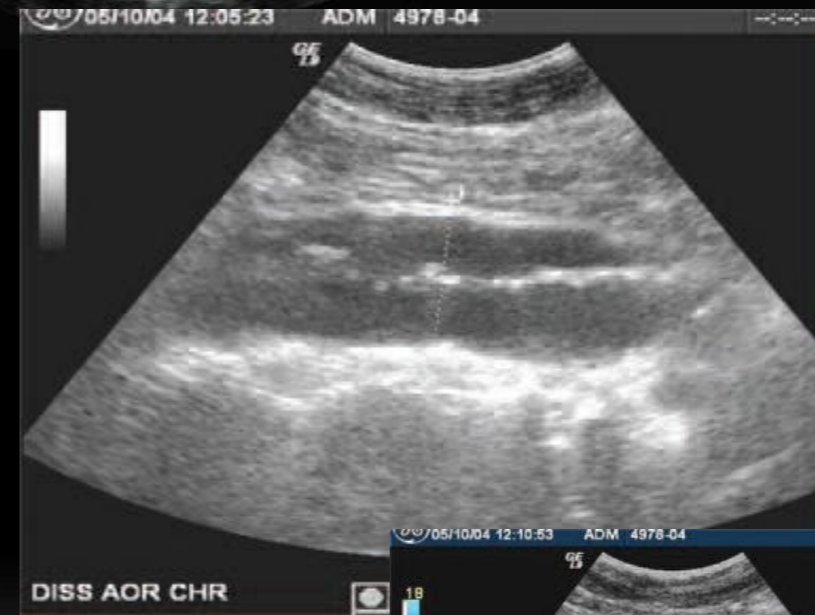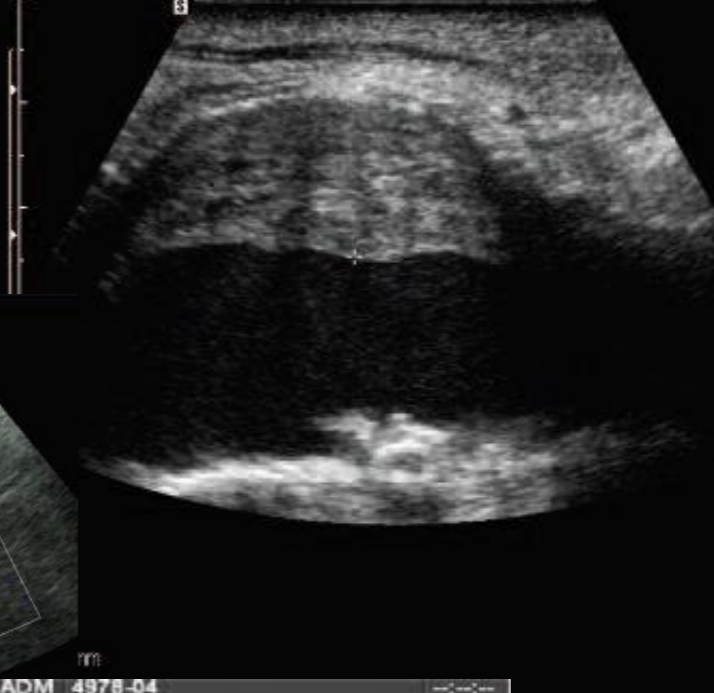
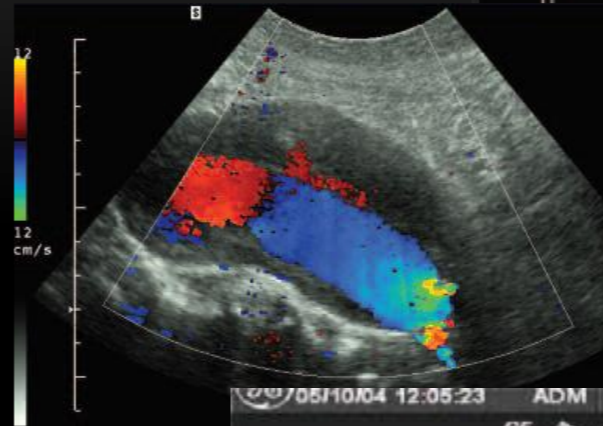
## LITT OM ANDRE ABDOMINALKAR

- Aorta
- Arteria mesenterica superior
- Vena cava inferior



# AORTA

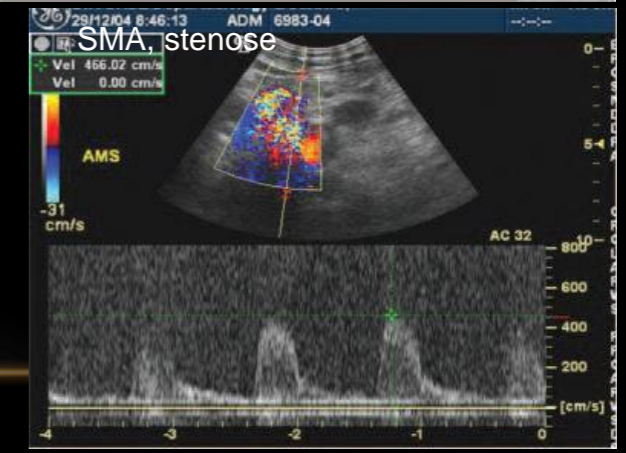
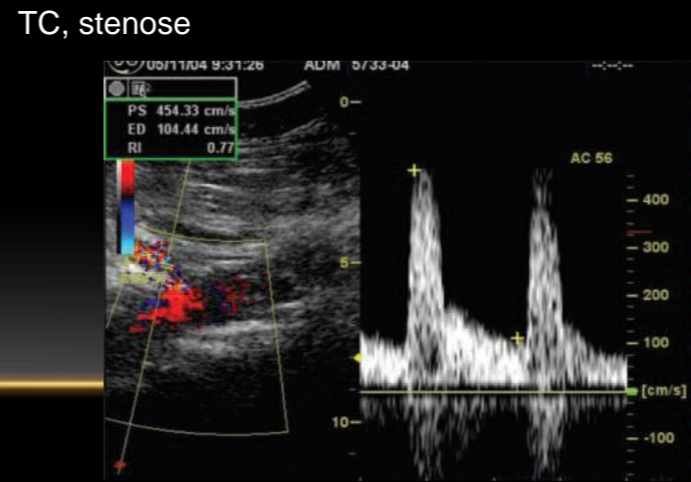
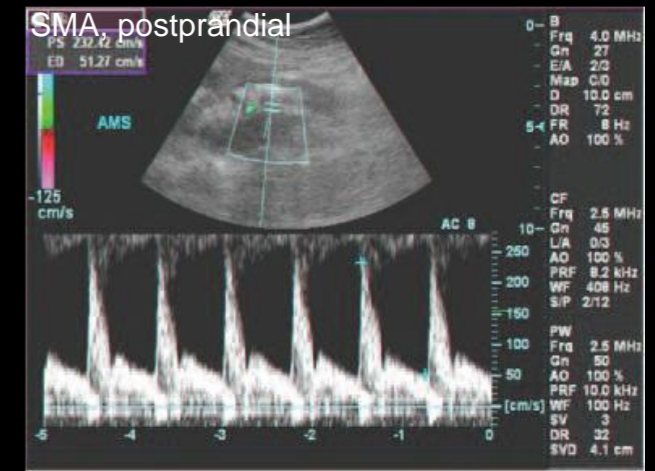
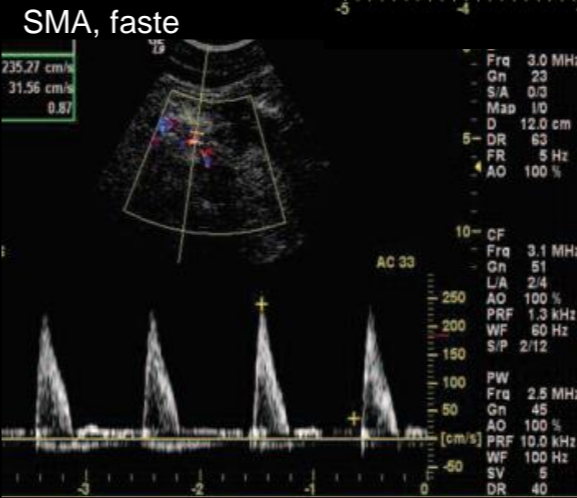
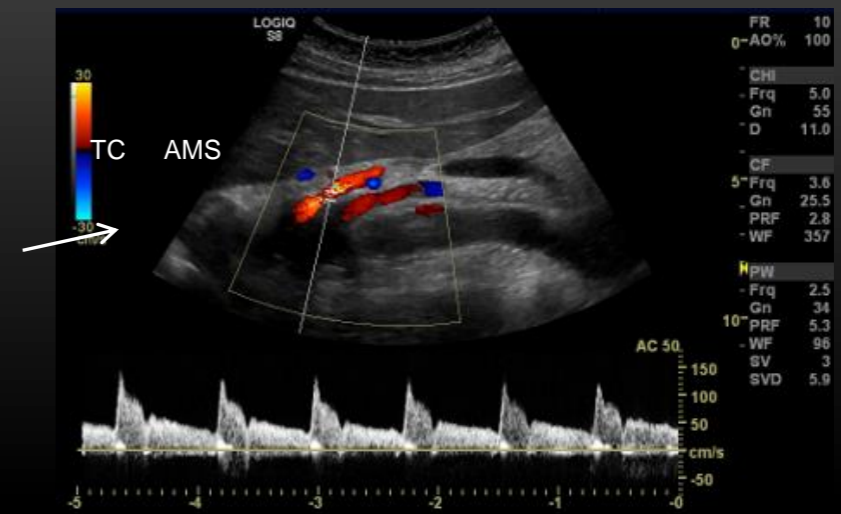
- Diameter 2-2,5cm
  - >3 cm AAA
- Plassering
  - Supra eller infrarenalt
  - Affiserer renalarterie?  
(Undersøke nyrer)
  - Affiserer iliacalkar?





# AMS OG TR. COELIACUS

- Øket flow etter måltid
  - Normalt
    - TC Ca 100cm/s
    - SMA: 95-140cm/s
  - Ingen flow/ retrograd flow/ kollateraler ved total okklusjon
  - Øket flow ved Intrastenotisk måling og inkomplett stenose
    - TC > 2m/s
    - SMA: > 2,75 (3)m/s, evt EDV > 45cm/s
- Ratio mot Aorta > 3 indikerer Høygradig stenose selv ved Lavere verdier







# HASTIGHETER I SMA

## Peak systolic velocity and EDV in the SMA

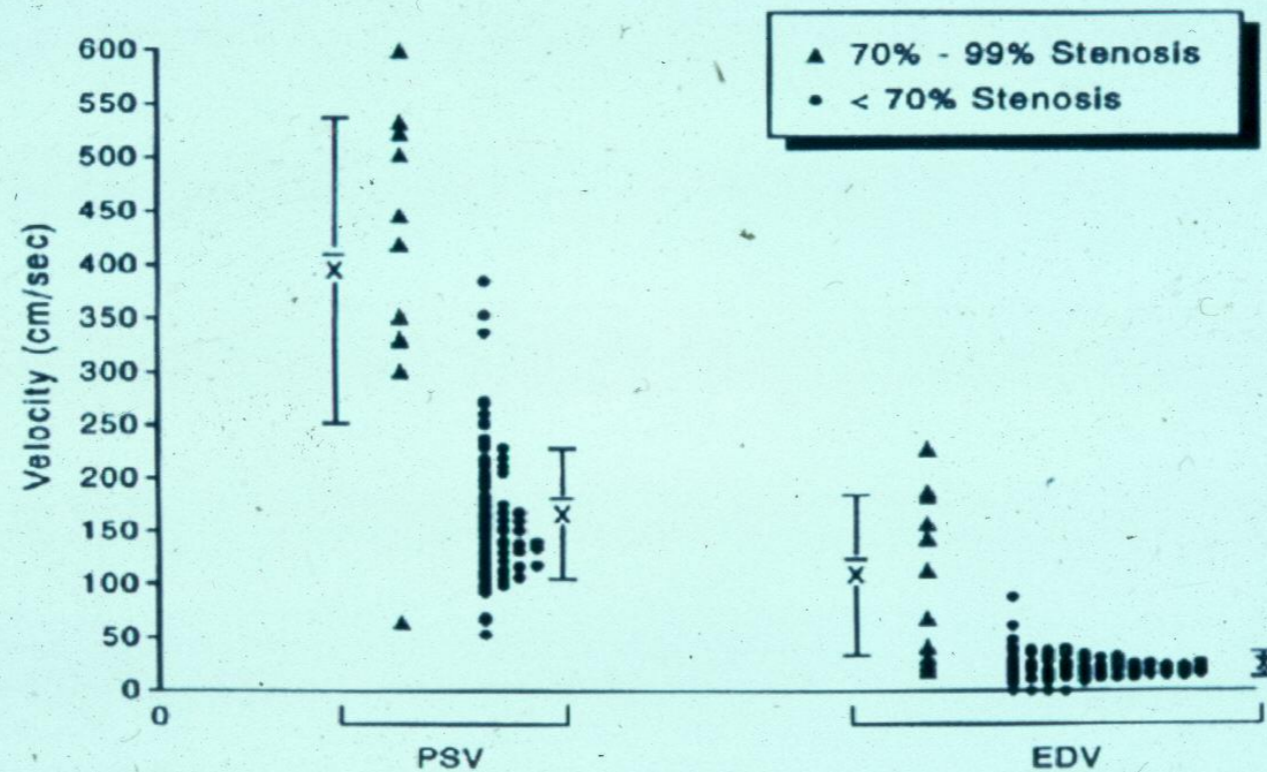


Figure 8. Peak systolic velocity and EDV in the SMA in those patients with  $\geq 70\%$  angiographic stenosis (▲) and  $< 70\%$  angiographic stenosis (●)  $P < 0.0001$ . (From Moneta GL, Lee RW, Yeager RA, et al: Mesenteric duplex scanning: A blinded prospective study. J Vasc Surg 17:79-86, 1993; with permission.)



# FYLLING AV VENA CAVA

Subxifoid el gjennom lever

- 2cm fra HA
- Exp og insp måling eller m-MODE
- Hypovolemi: >50% kollaps i inspirasjon
- Hypervolemi: minimalt kollaps

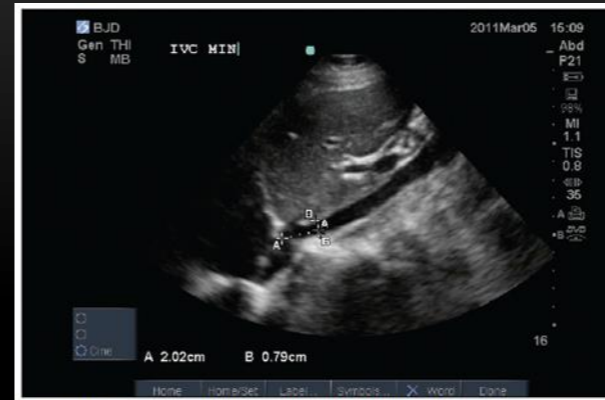

Figure 2. Image shows inspiratory (minimal) diameter of the IVC.

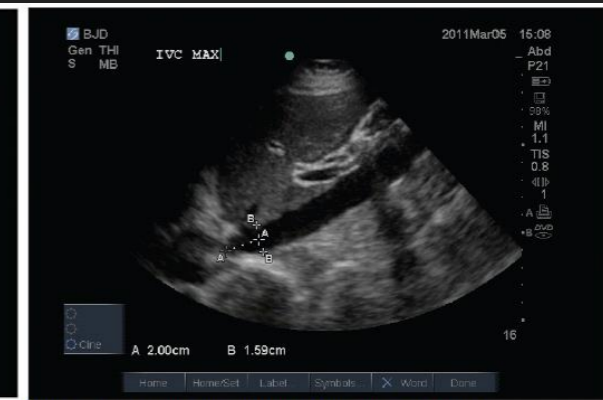

Figure 3. Image shows expiratory (maximal) diameter of the IVC.

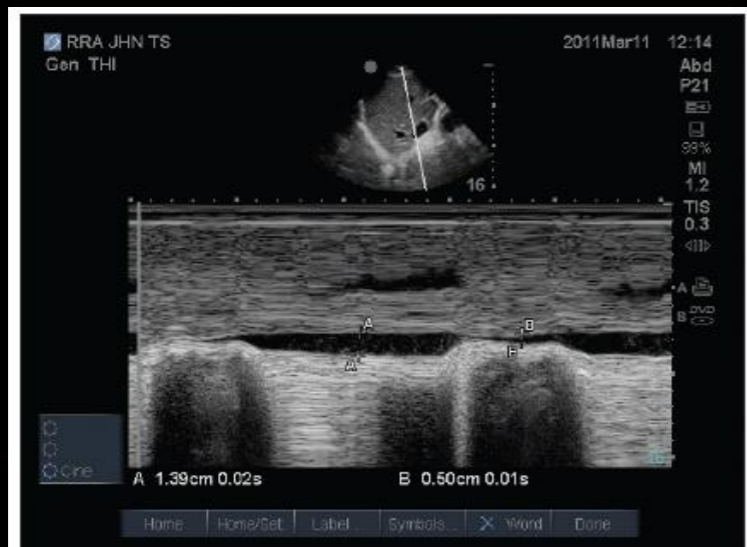

Figure 4. Expiratory diameter in M-mode is measured at largest site.

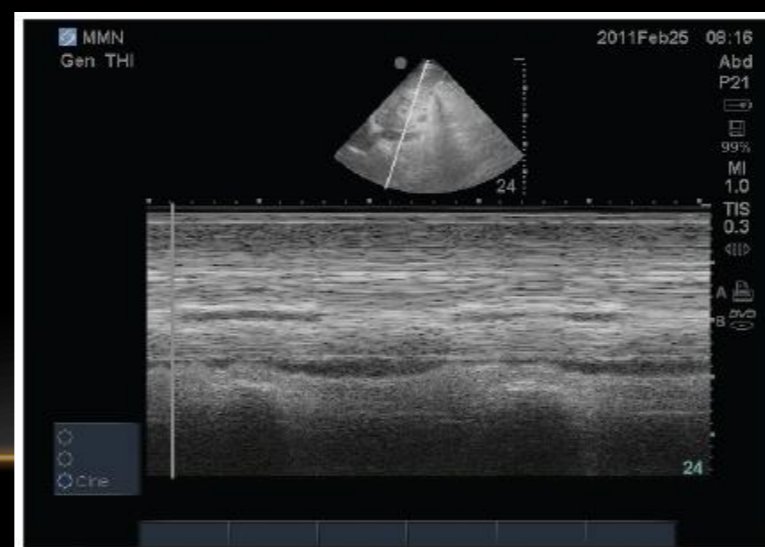

Figure 6. With volume depletion, the IVC can be hard to visualize.

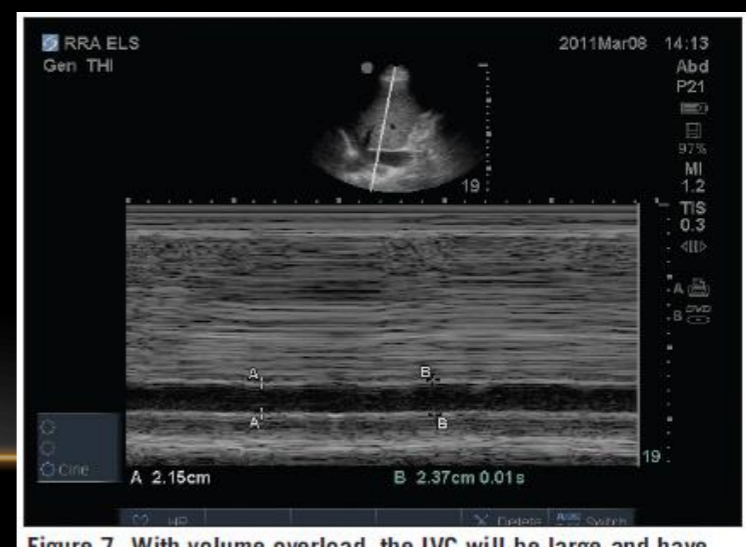


Figure 7. With volume overload, the IVC will be large and have minimal collapse on inspiration.





# OPPSUMMERING: LEVERARTERIE: NORMAL VS TARDUS-PARVUS

## Subjective evidence

*Tardus-parvus* waveform

## Objective evidence

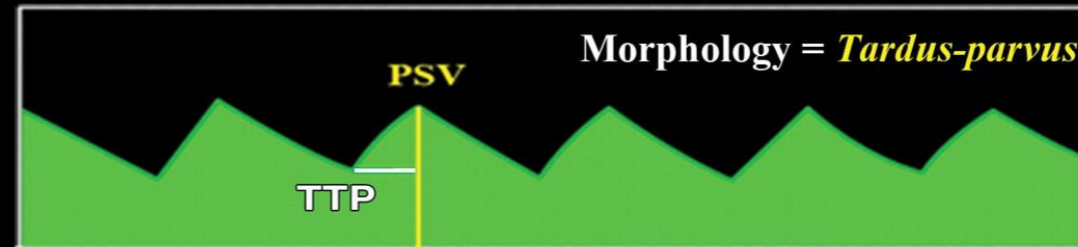
Acceleration\* < 5 m/sec<sup>2</sup>

Time-to-peak > 70 msec

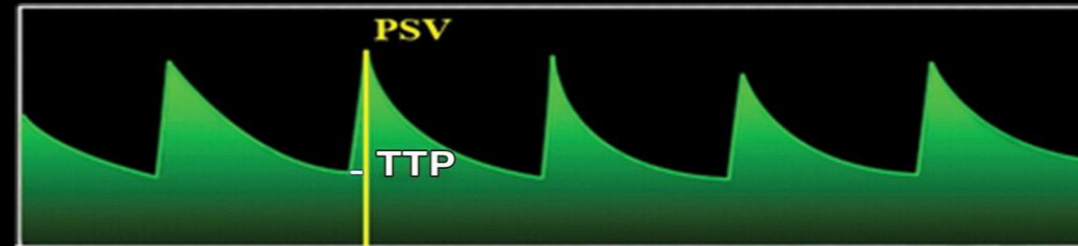
Low RI (value depends on vessel)

Rød  
Pulsatil  
RI 0.55–0.81

Upstream  
stenosis



Normal



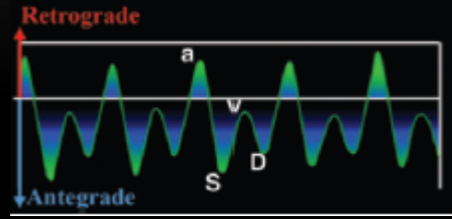
\*Acceleration = PSV / TTP

Tardus = sen, Parvus = lav

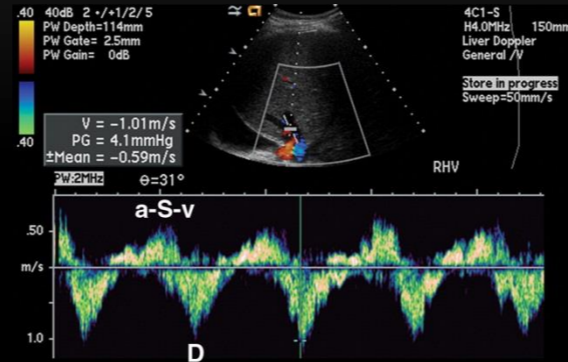



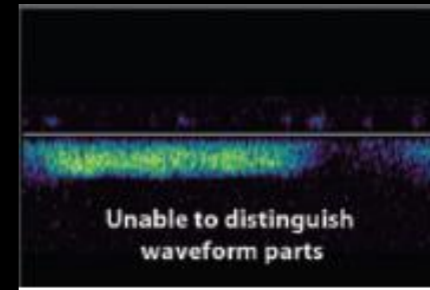
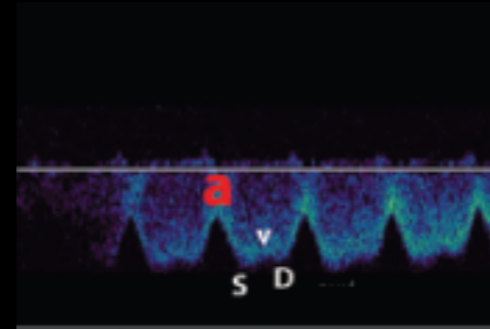
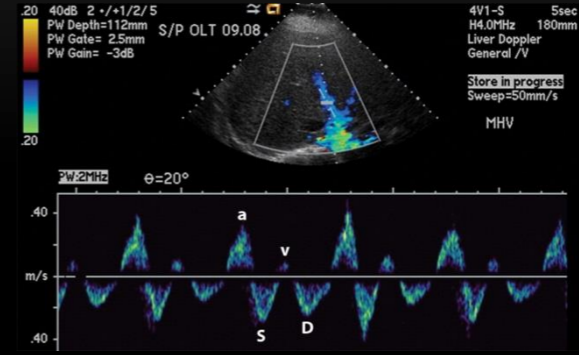
# OPPSUMMERING LEVERVENE



Pulsatil eller redusert fasitet



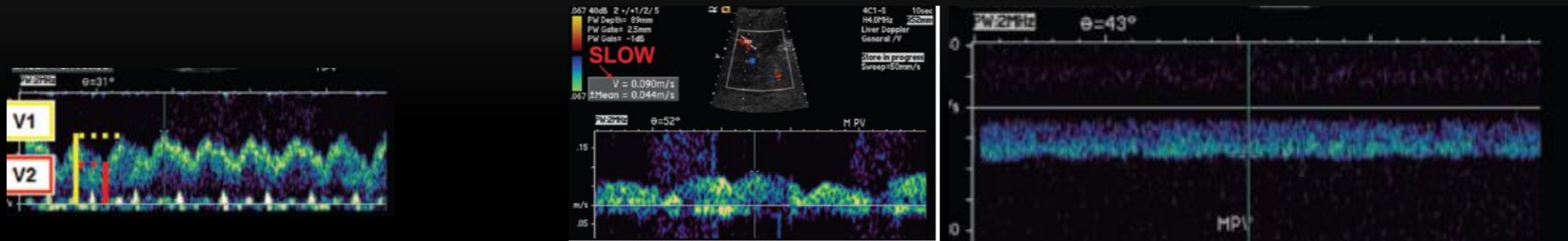
Hjertesvikt med eller uten TI



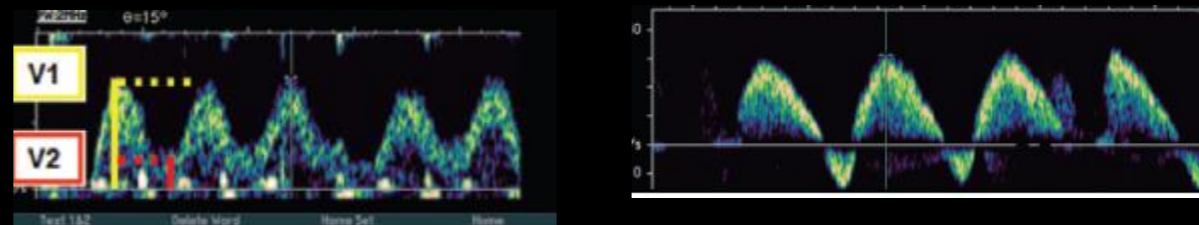
Portal hypertensjon



# OPPSUMMERING PORTVENE



Portal hypertensjon ; redusert hastighet eller reversering



Høyre hjertesvikt