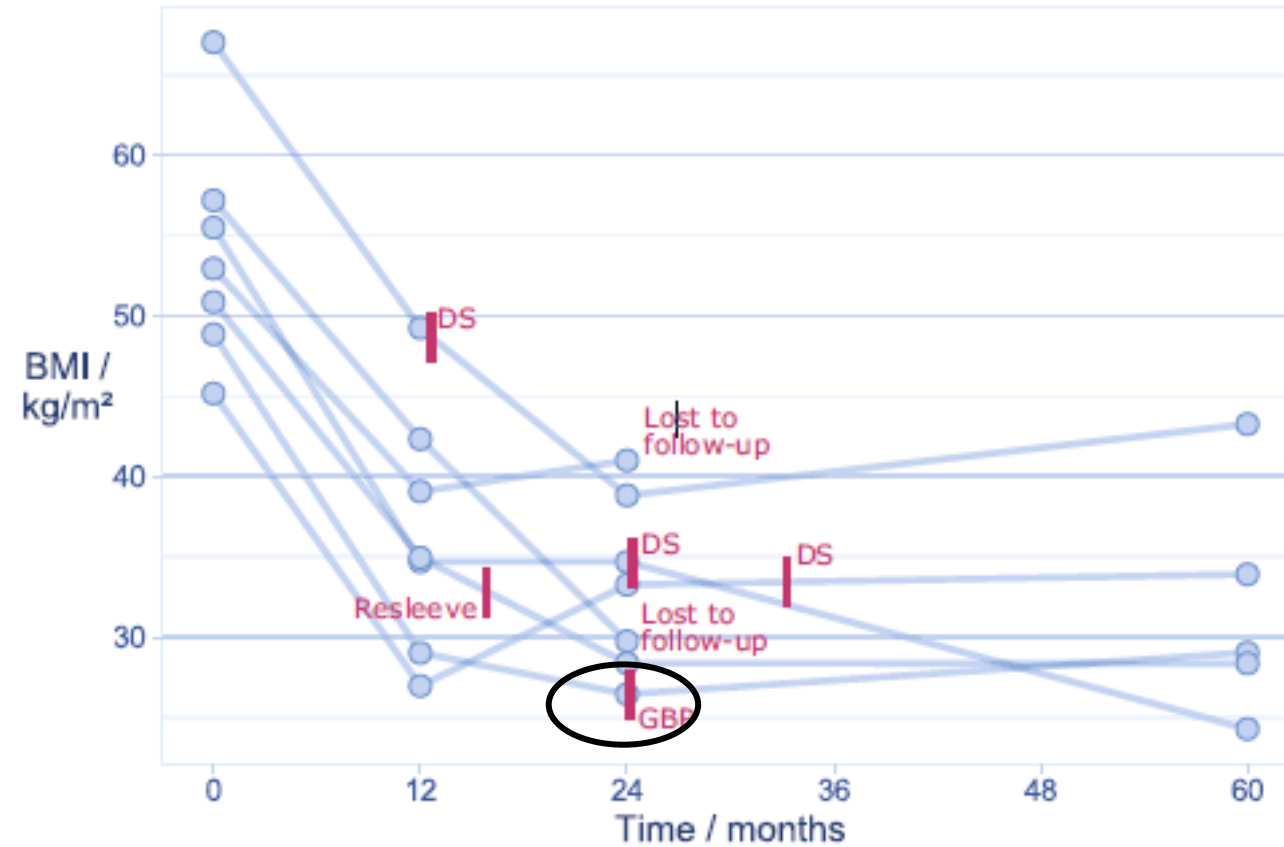


Hill's operation for reflux after bariatric surgery (sleeve)

villy.vage@helse-bergen.no

Sleeve: Revisions during five years $7/168 = 4.2\%$ (1 due to reflux, 6 due to obesity)



Sleeve converted to RYGBP for reflux (n=9)

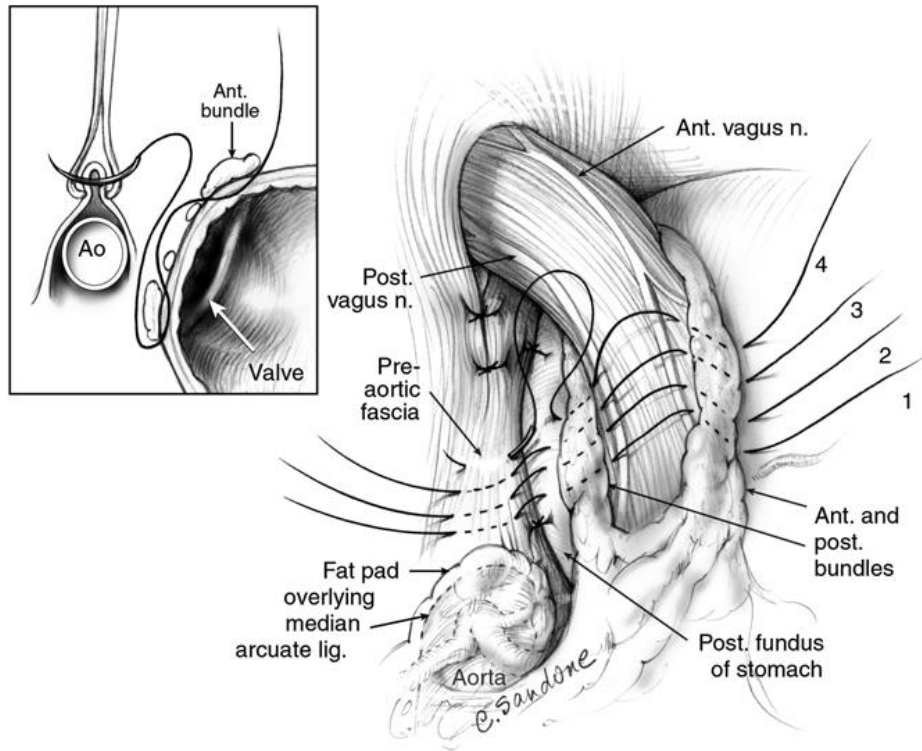
After two years:

- 4/9 without PPI
- But also 2/9 had a laparotomy due to acute abdominal pain:
 - One = no finding
 - One = small bowel ileus due to adhesions

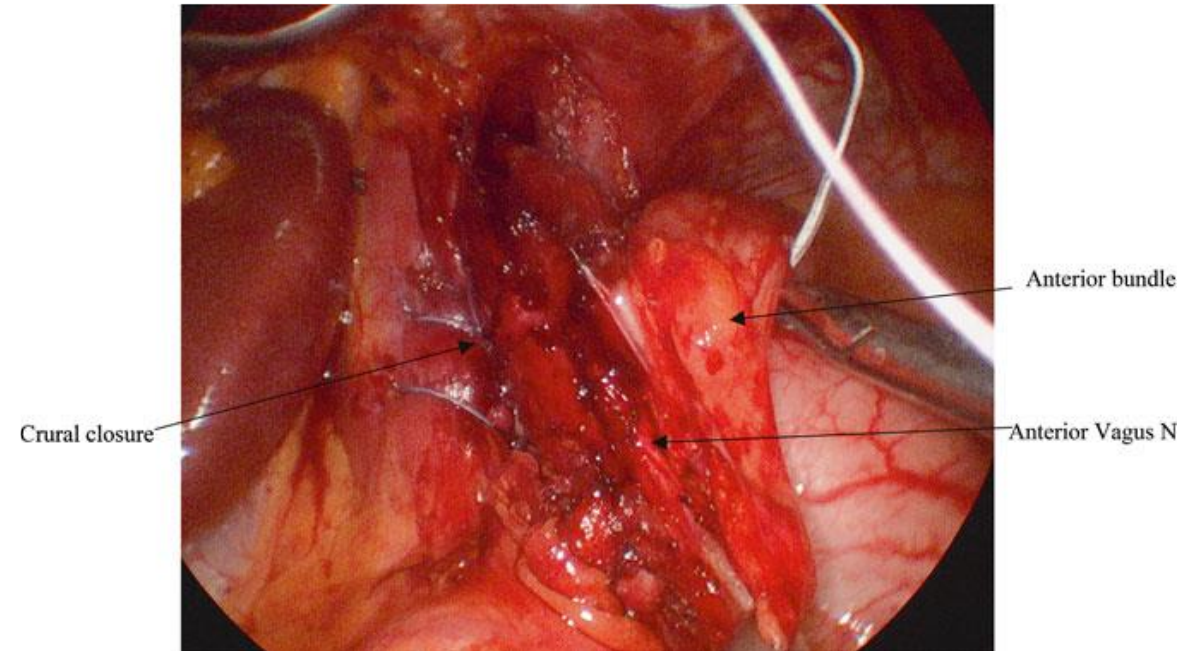
DO WE HAVE ANYTHING BETTER?

Hill's

Hill sutures:

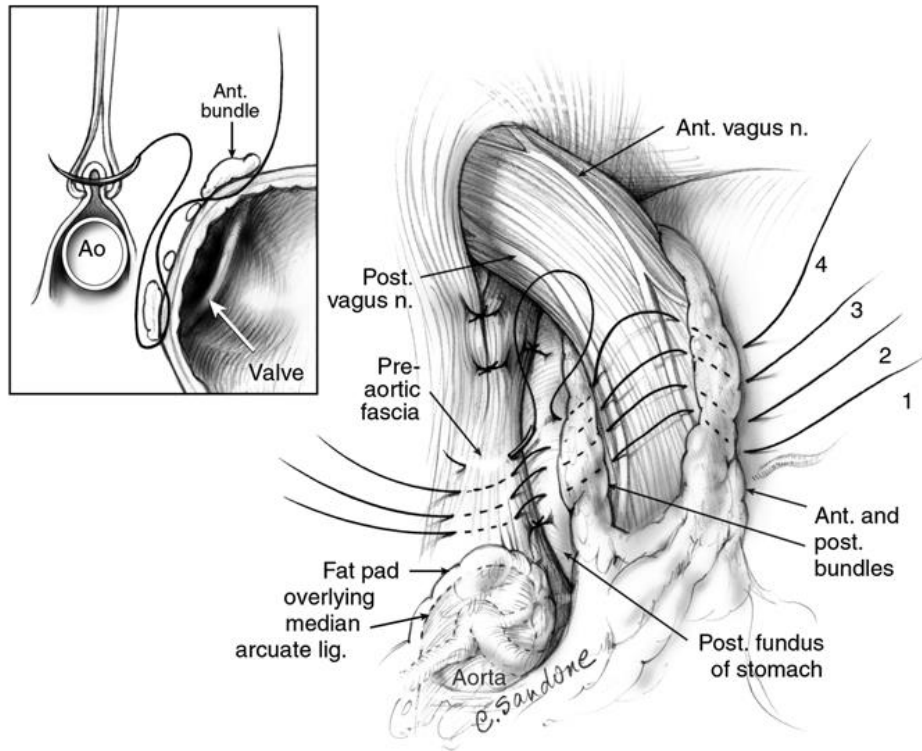


First suture, first stitch:

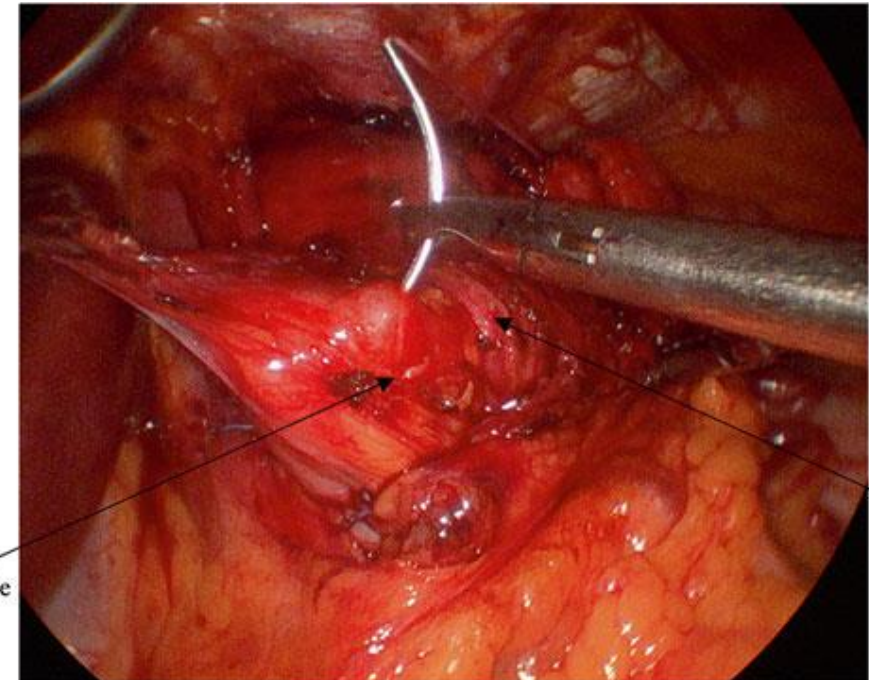


Hill's

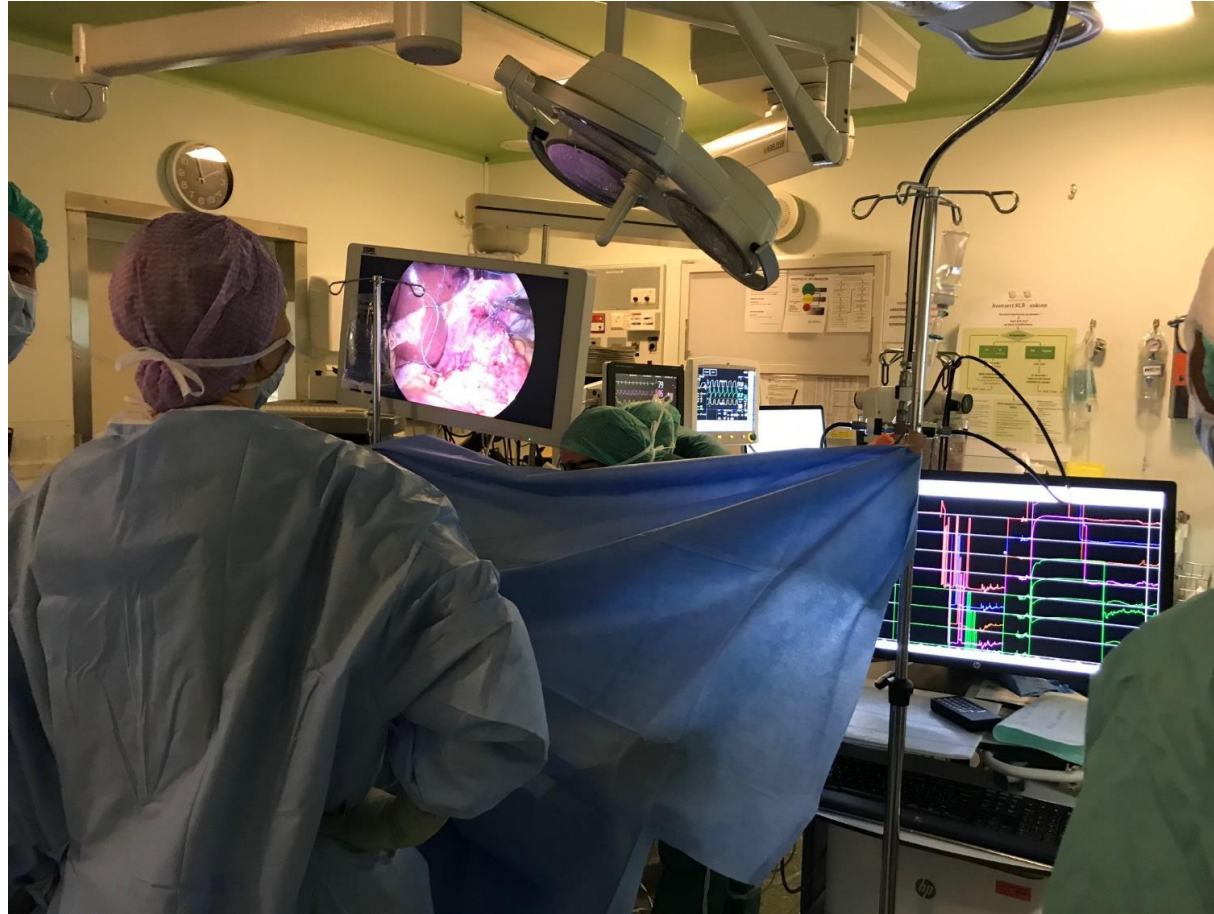Hill sutures:



First suture, second stitch:



Hill's with peroperative manometry



Conclusions

- Laparoscopic Hill operation show promising results
- The first choice for surgical treatment of reflux after sleeve (?)
- Should only be done in departments where a vascular surgeon is available