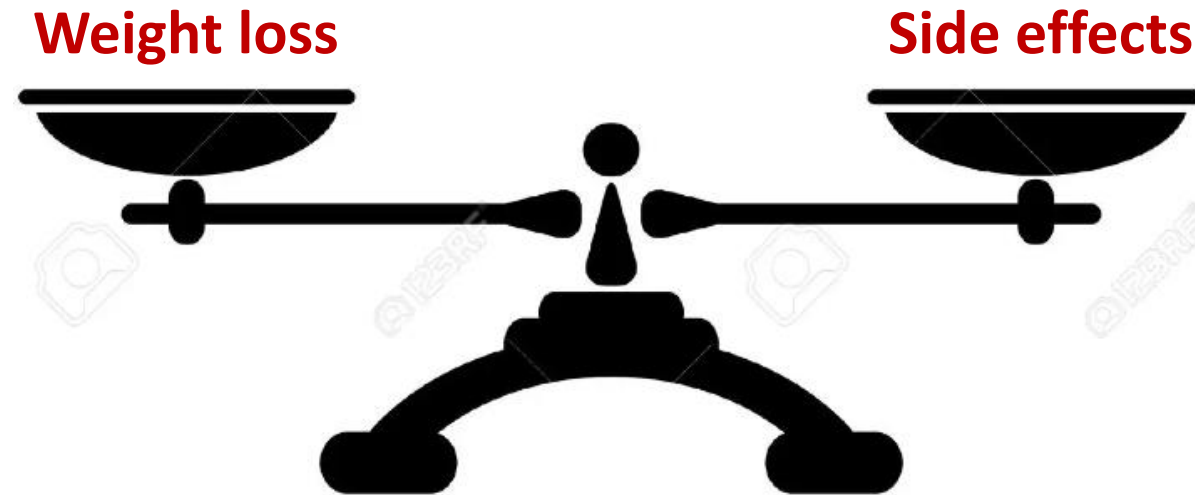

Anatomy of the Lower Oesophageal Sphincter and an update on the Sleeve Pex study

Villy Våge

Bariatric surgery – outcome:



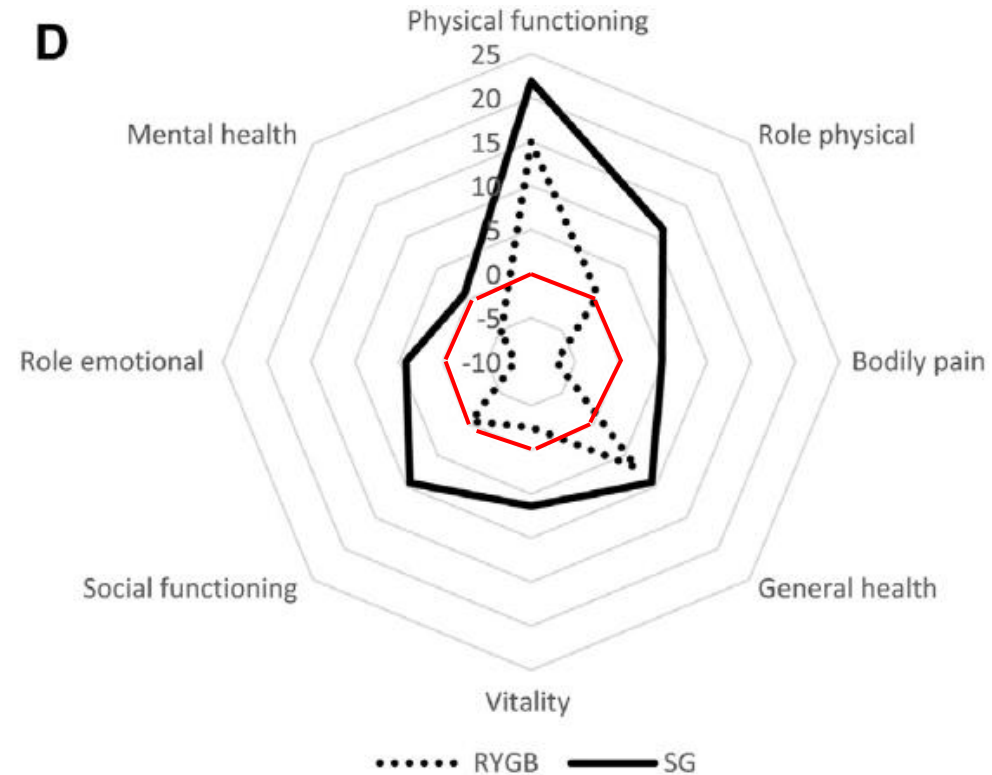


Original article

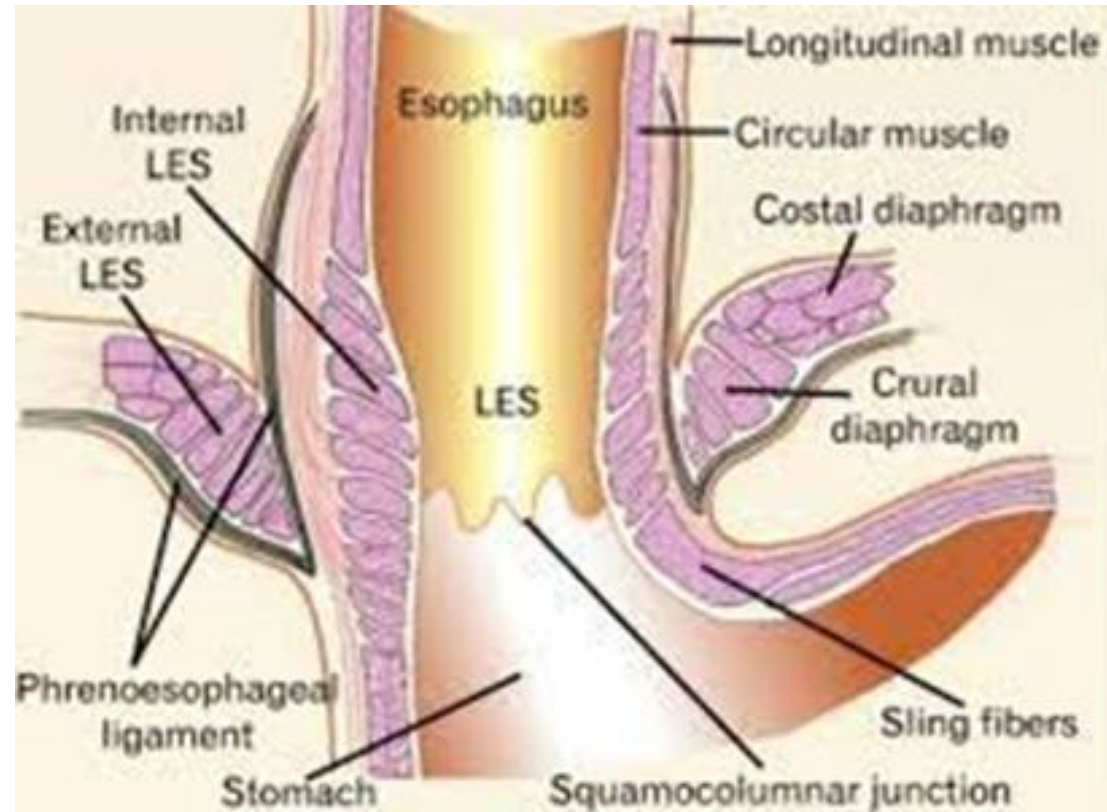
Chronic abdominal pain and quality of life after Roux-en-Y gastric bypass and sleeve gastrectomy – a cross-cohort analysis of two prospective longitudinal observational studies

Monica Chahal-Kummen M.D.^a [👤](#) [✉](#), Villy Våge Ph.D.^b, Jon A. Kristinsson Ph.D.^c,
Tom Mala Ph.D.^d

SF-36 scores two yrs after Sleeve & RYGBP for patients with CAP (RYGBP: 60/209 (28.7%), Sleeve: 50/186 (26.9%)).

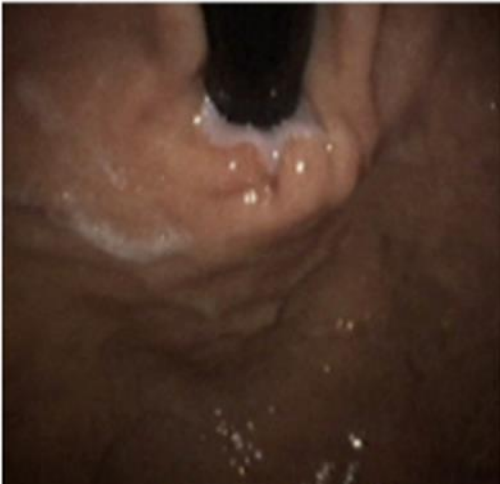

Normal anatomy

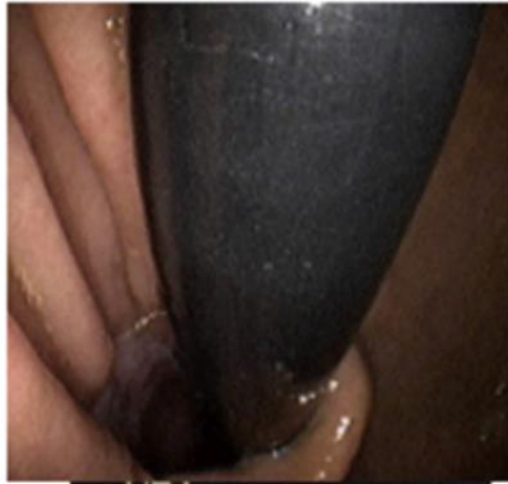

Hill's grading

Grade I

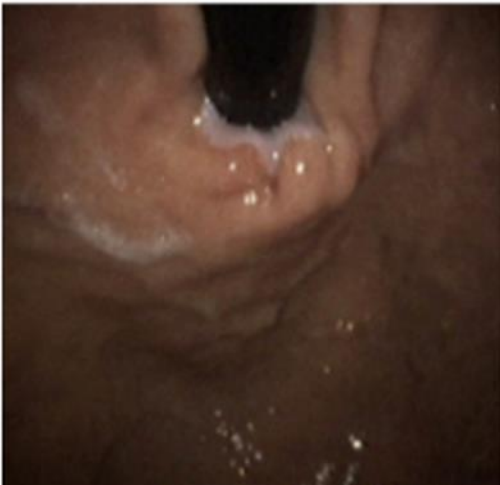

Grade II

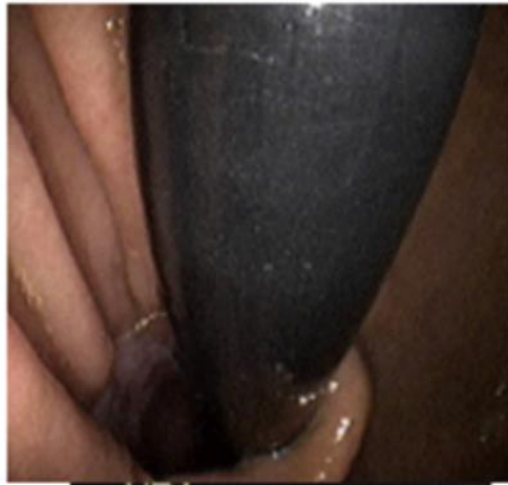

Hill's grading

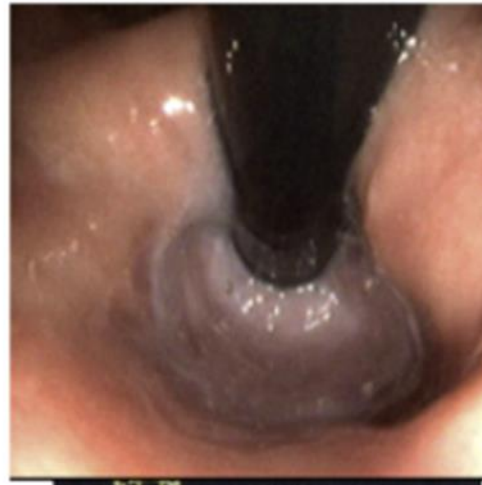
Grade I



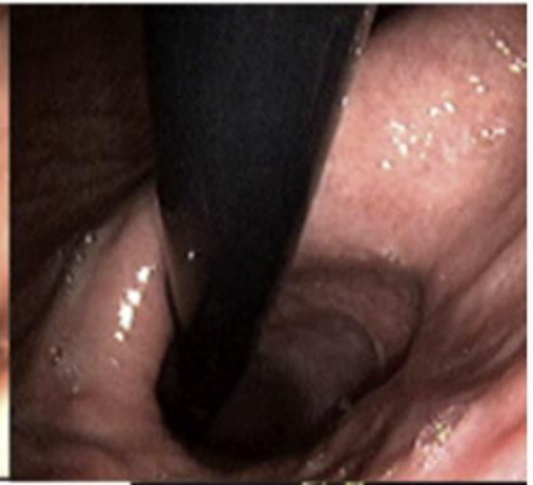Grade II



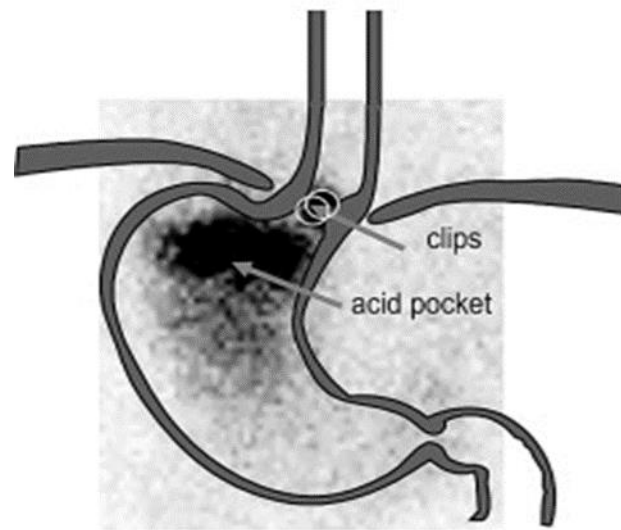
Grade III



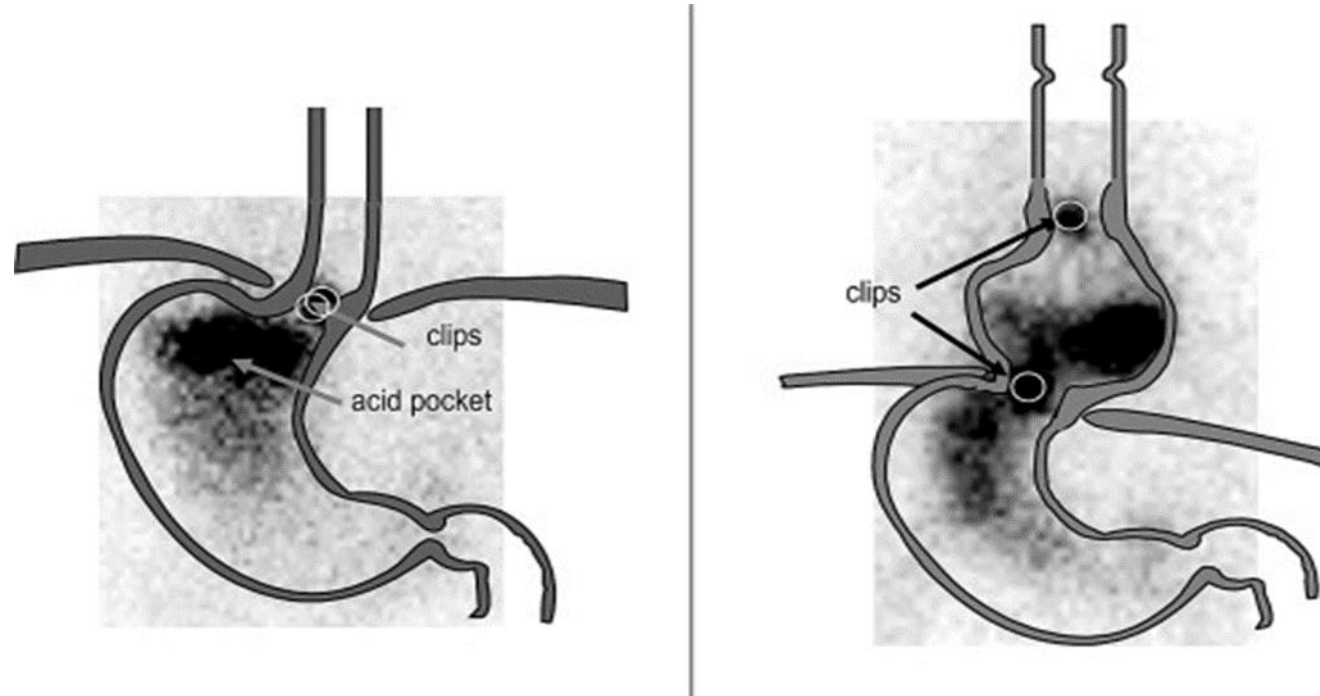
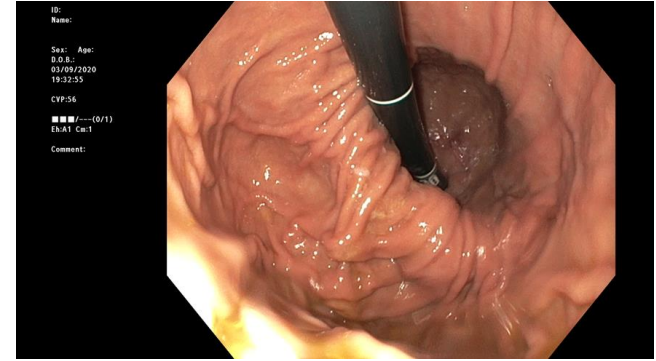
Grade IV



Acid pocket and hiatal hernia

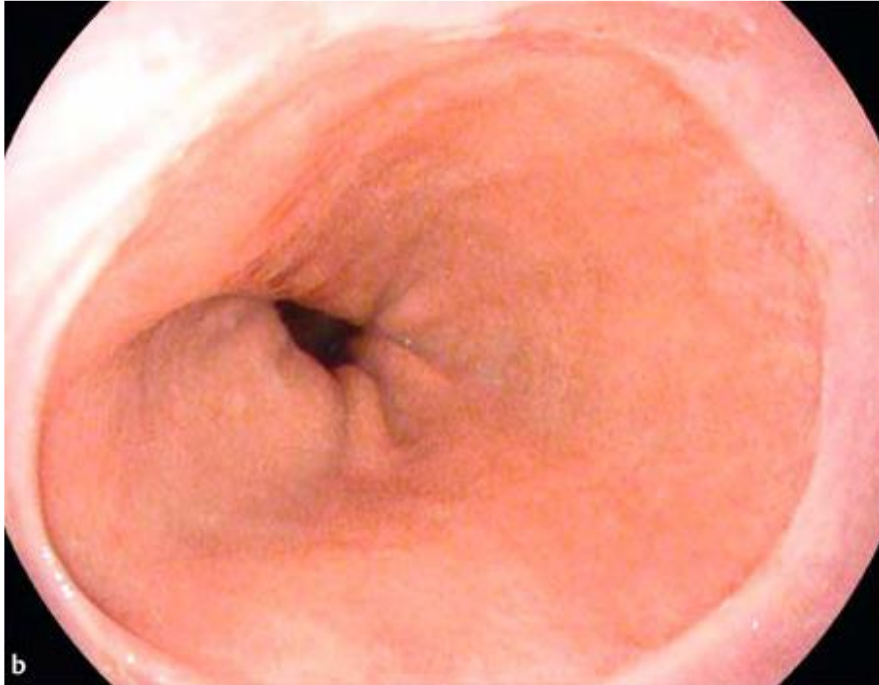

Acid pocket and hiatal hernia



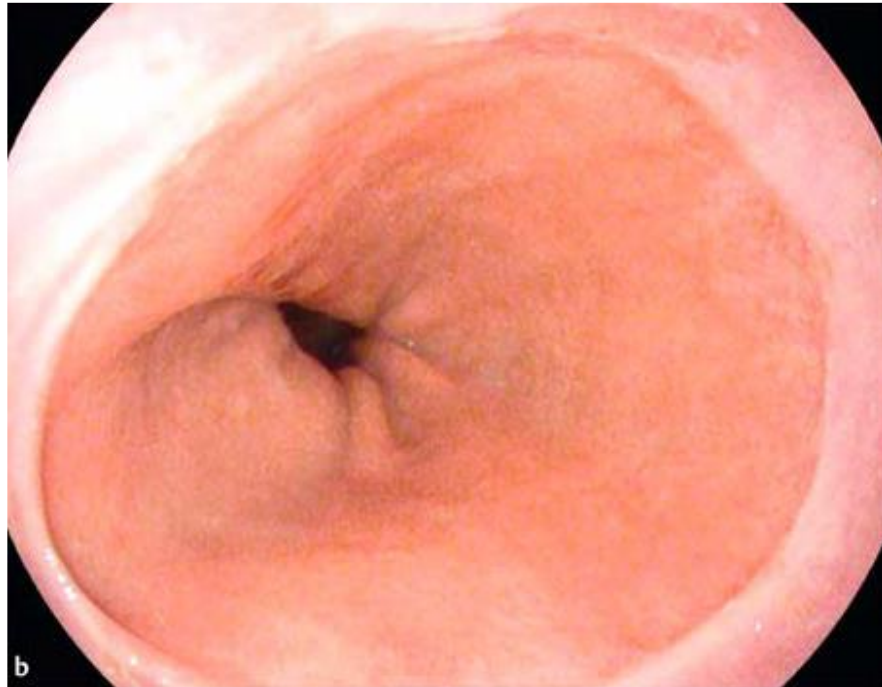
Where is the GO junction?

Barret?

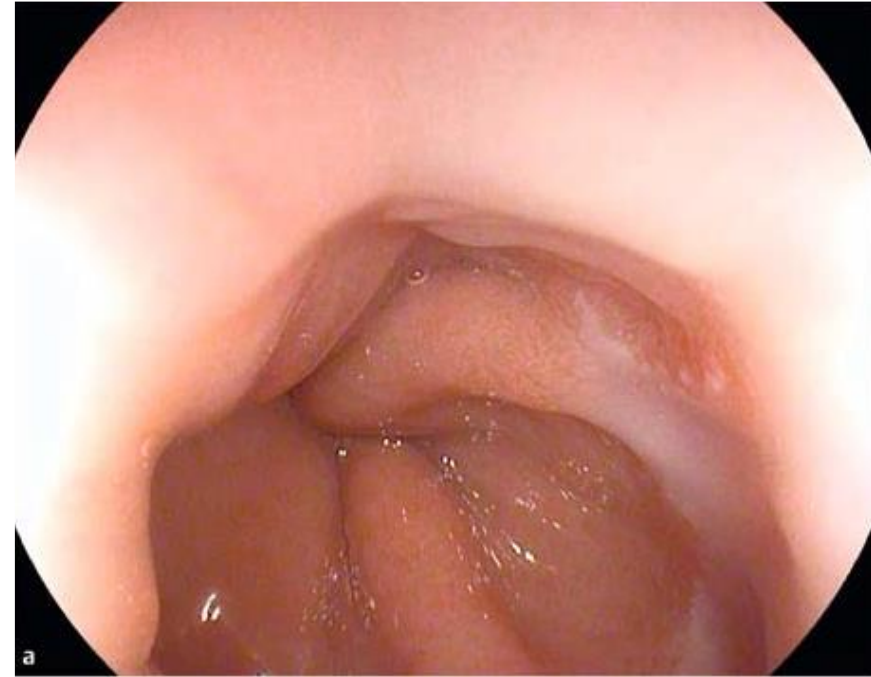

Where is the GO junction?

Barret?



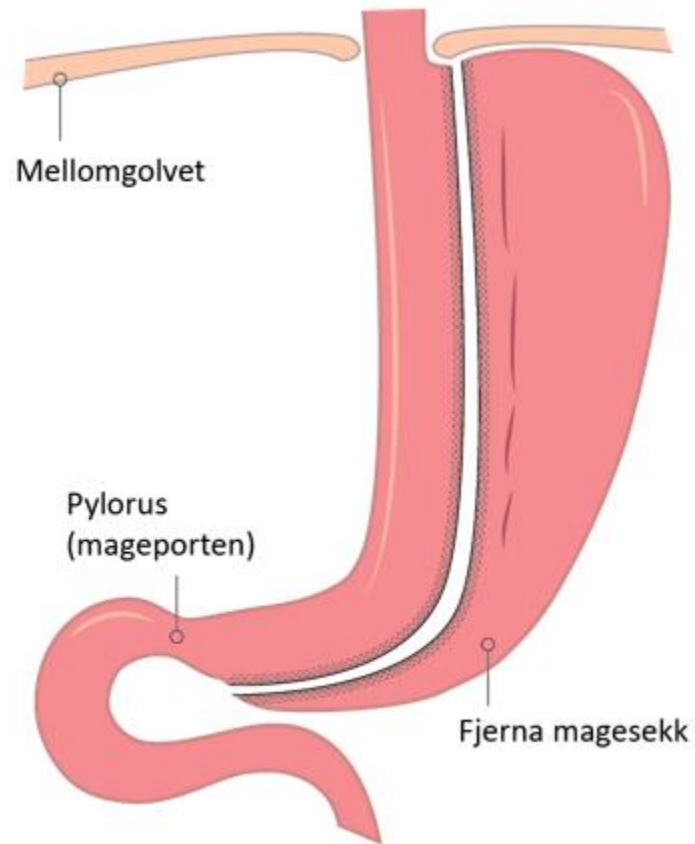
Only a hiatal hernia!



The Sleeve Pex study

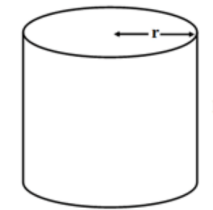
A short overview

Geometri: Sleeve \approx cylinder



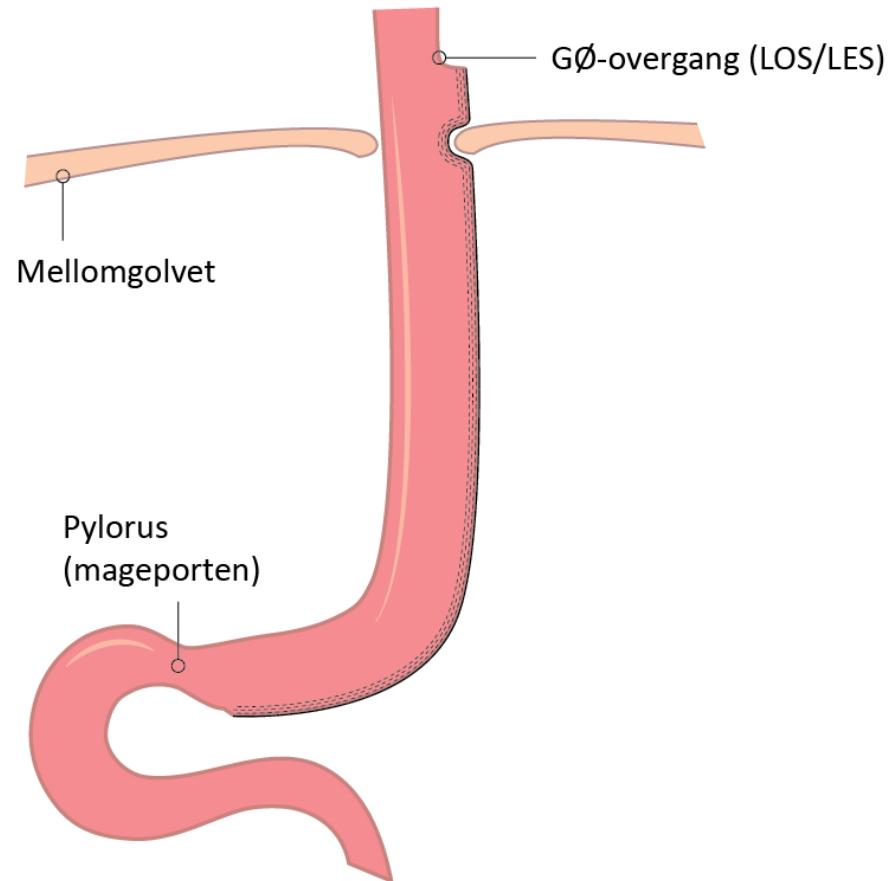
- **Size**

$$V = \pi r^2 h$$



- **Position** (and form)

Sleeve Pex hypothesis



Hypothesis:

- Neo-reflux is mainly caused by intrathoracic migration of the gastric remnant
- We must prevent such migration

Criteria:

Inclusion

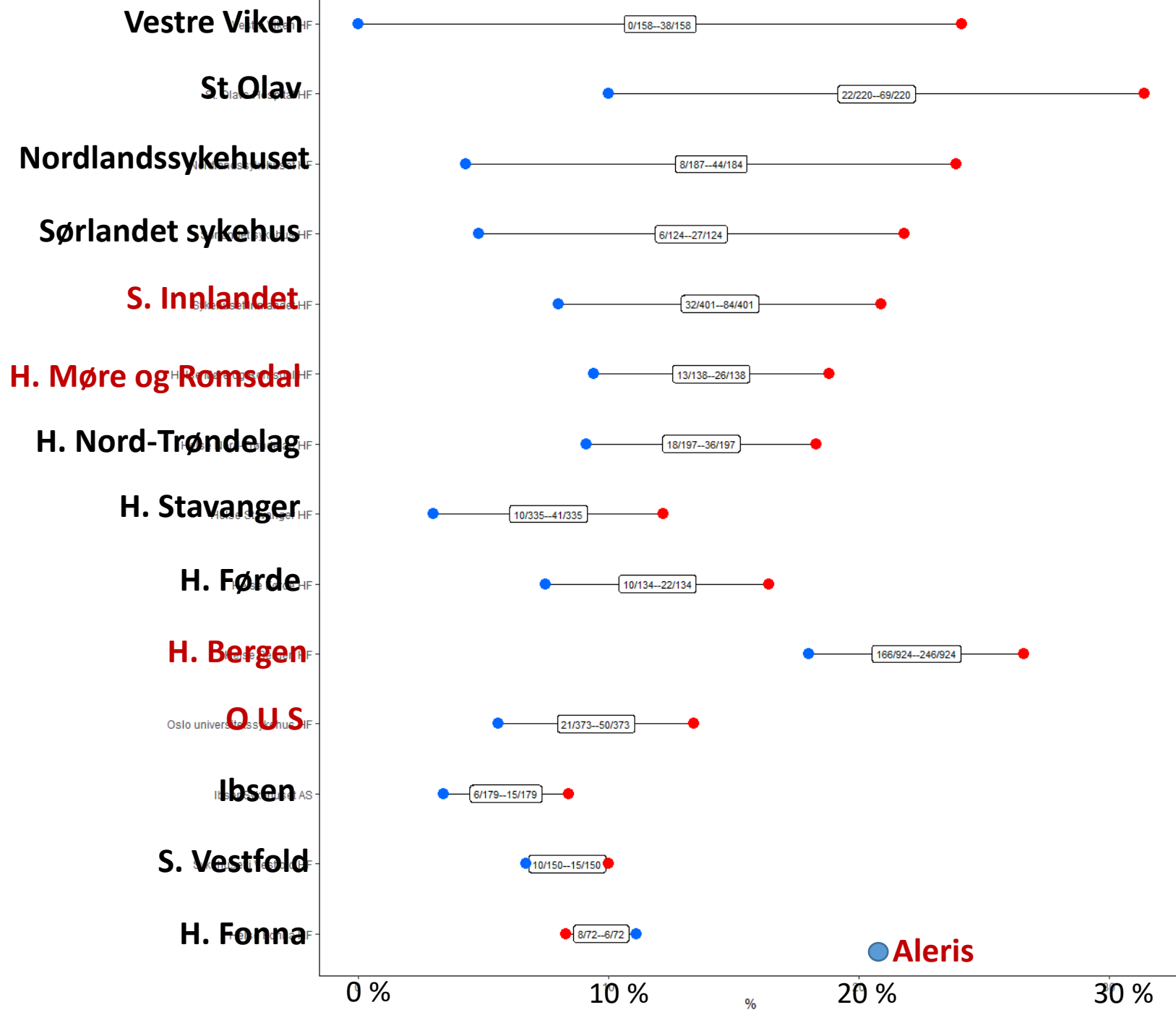
- BMI \geq 35 planned for sleeve

Exclusion

- Age < 18 yrs
- Previous bariatric surgery
- Previous reflux surgery
- Using ARM for other reason than reflux
- Unable to understand GerdQ questionnaire
- Sleeve planned as part I of a DS

Sleeve Pex: Endpoints at 2 yrs

- Primary endpoint:
 - Continuous use of ARM due to reflux symptoms or reoperations due to GORD
- Secondary endpoints:
 - Patient reported outcome (HRQL and GerdQ)
 - Endoscopy and pH-metry (wireless - Bravo) in a subgroup (n=30)



Aleris