



Nasjonalt Senter for Gastroenterologisk Ultrasonografi

National Centre for Ultrasound in Gastroenterology
Haukeland University Hospital, Bergen, Norway

Ultrasound of the Gallbladder and biliary tract

Odd Helge Gilja, MD, Ph.D.

Professor

Department of Clinical Medicine

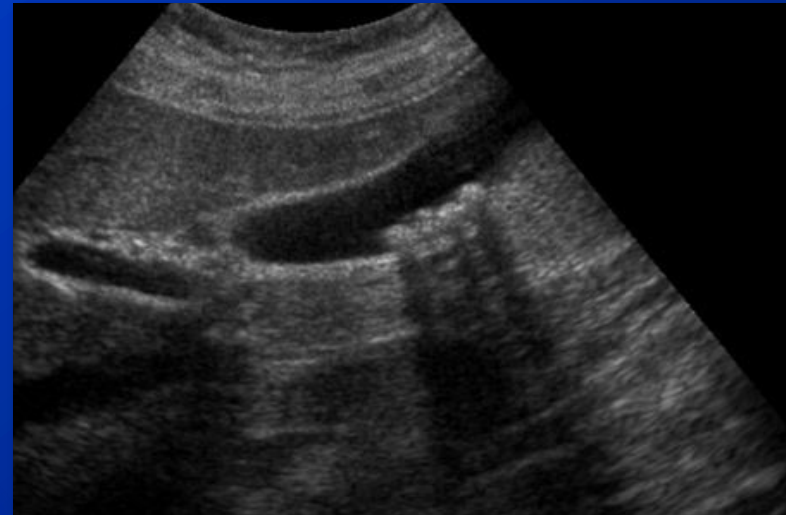University of Bergen



Ultrasound and the Biliary Tract

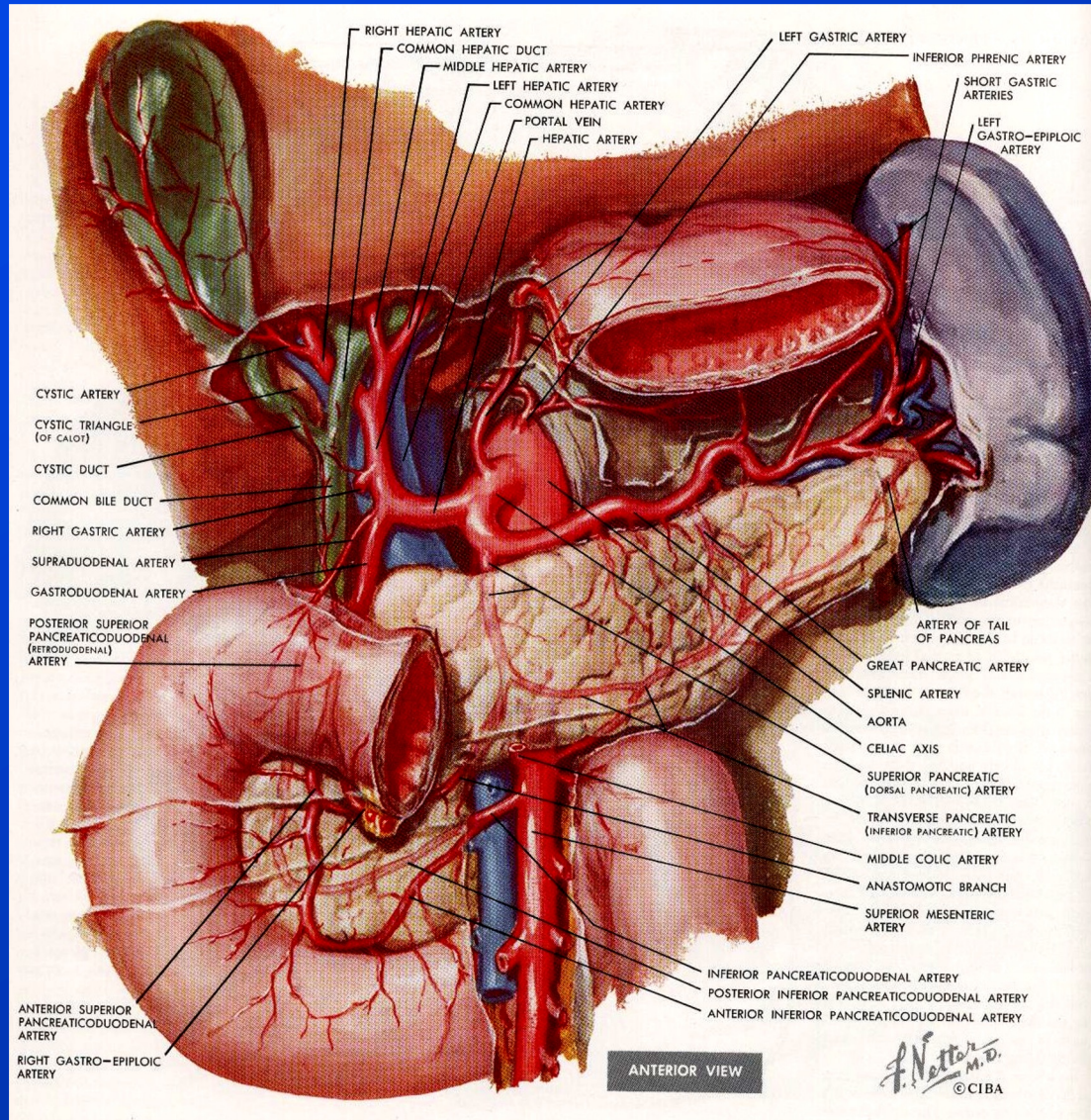
- Gallbladder:
 - Stones
 - Polyps
 - Cholecystitis
 - Tumours
- Biliary Ducts:
 - Intrahepatic dilatation
 - Ekstrahepatic dilatation
 - Cholangitis
 - Cysts (Carolis syndrom)
 - Cholangiocarcinoma

Ultrasound is the
method of choice



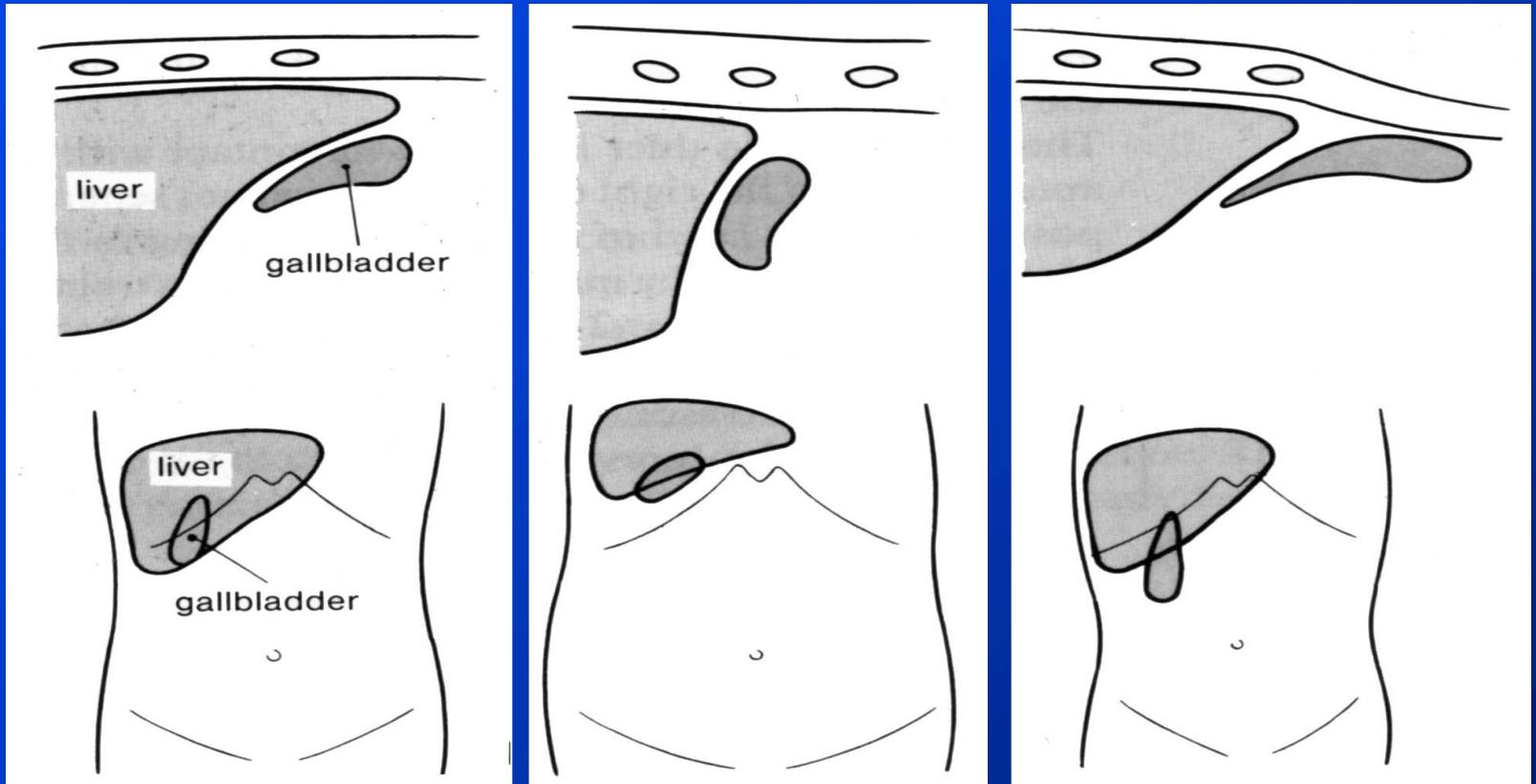


NORMAL ANATOMY



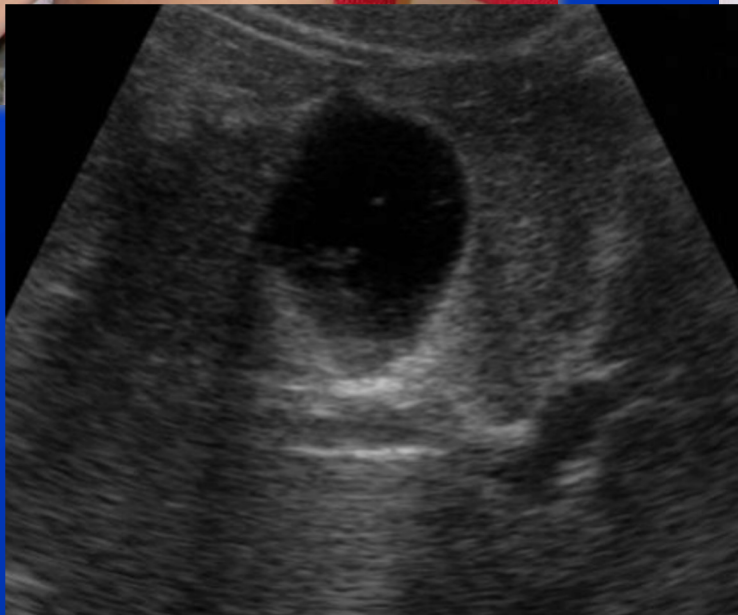
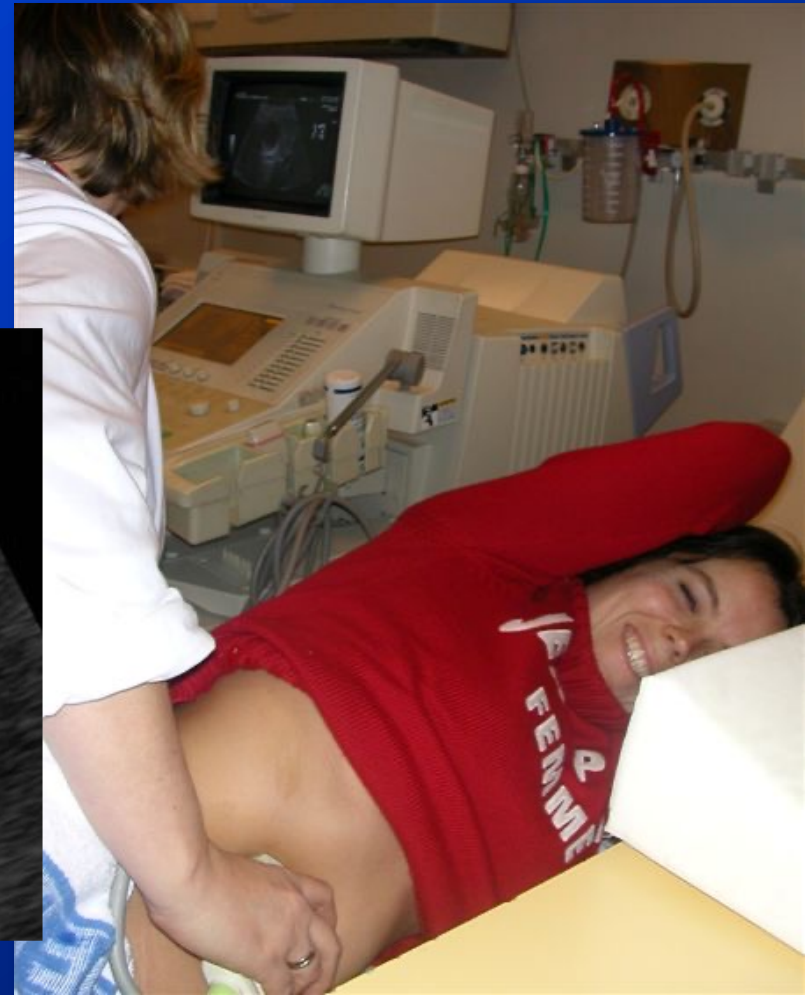
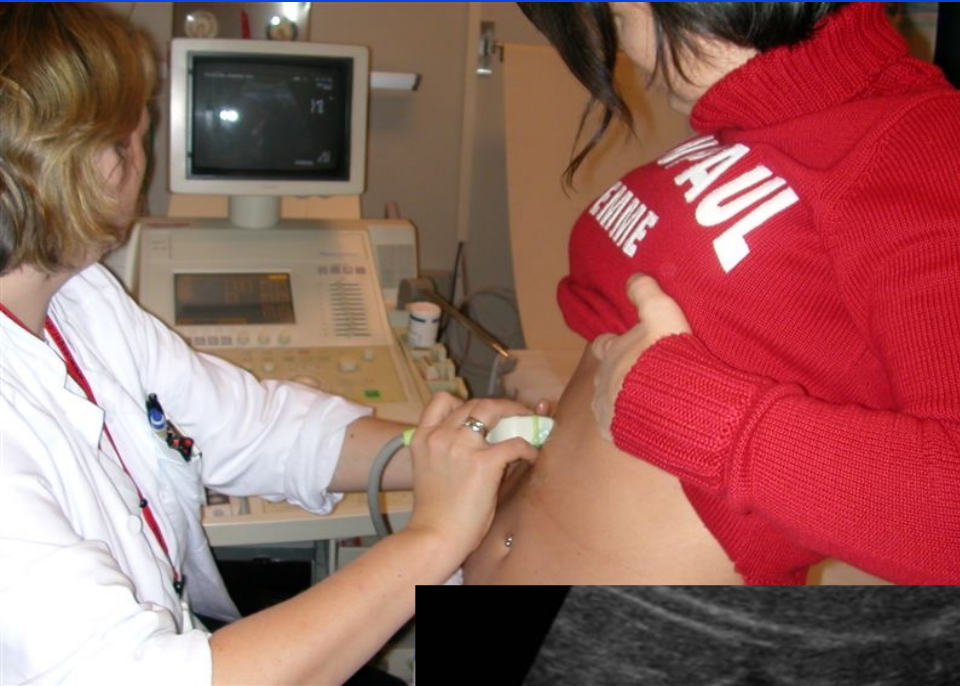
Gallbladder - Variable Position



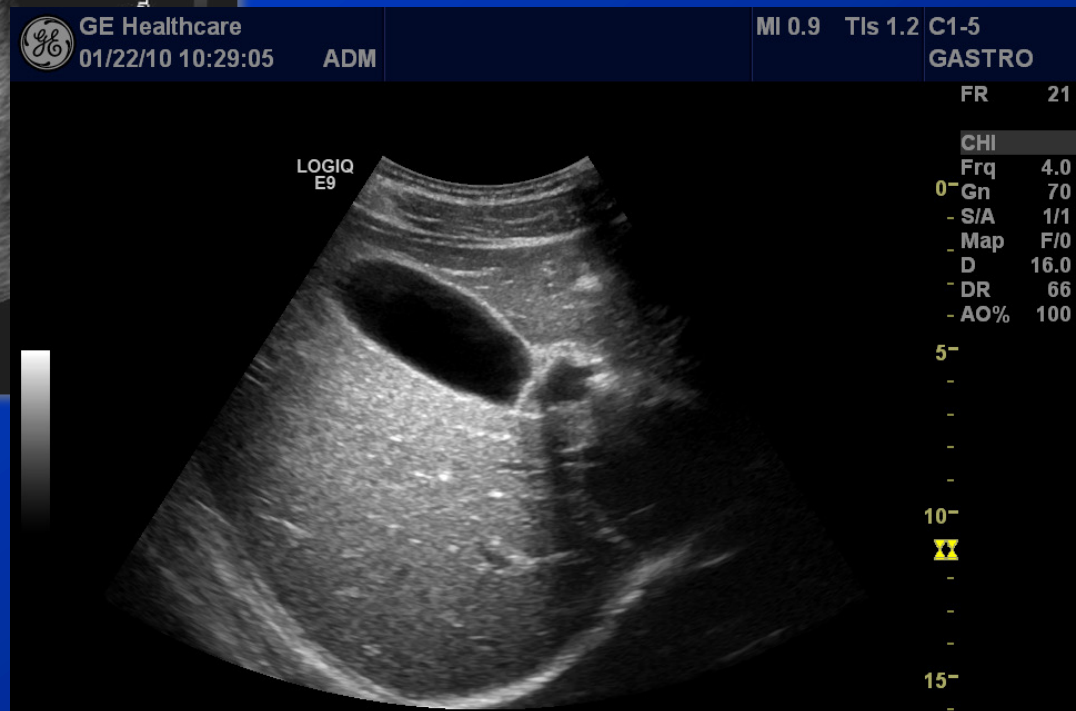
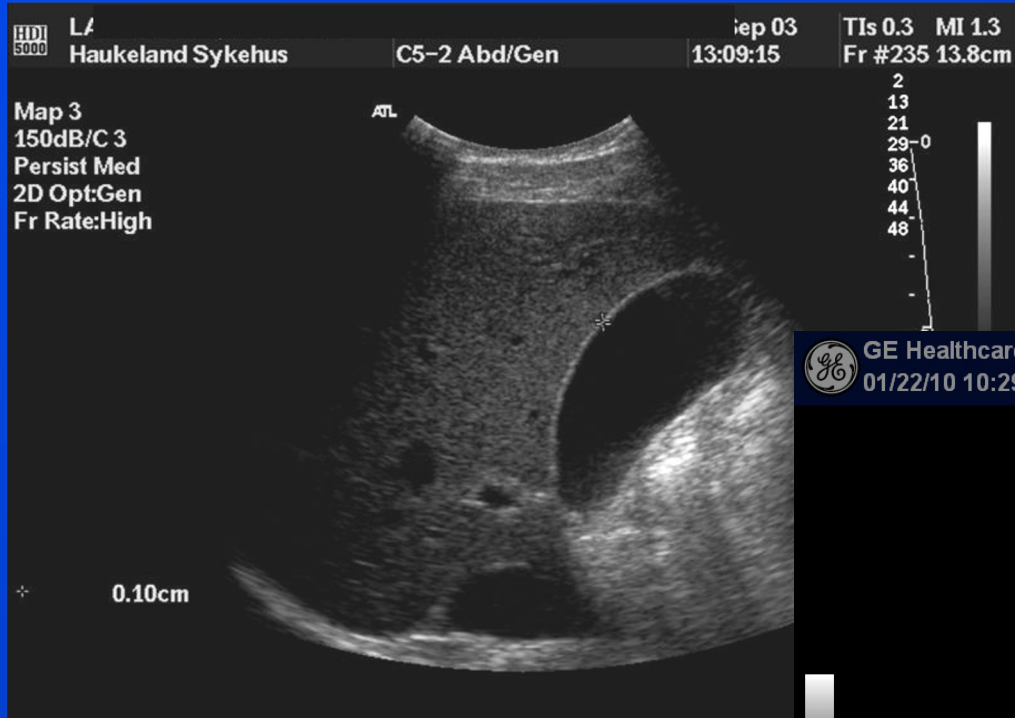

Examination Technique



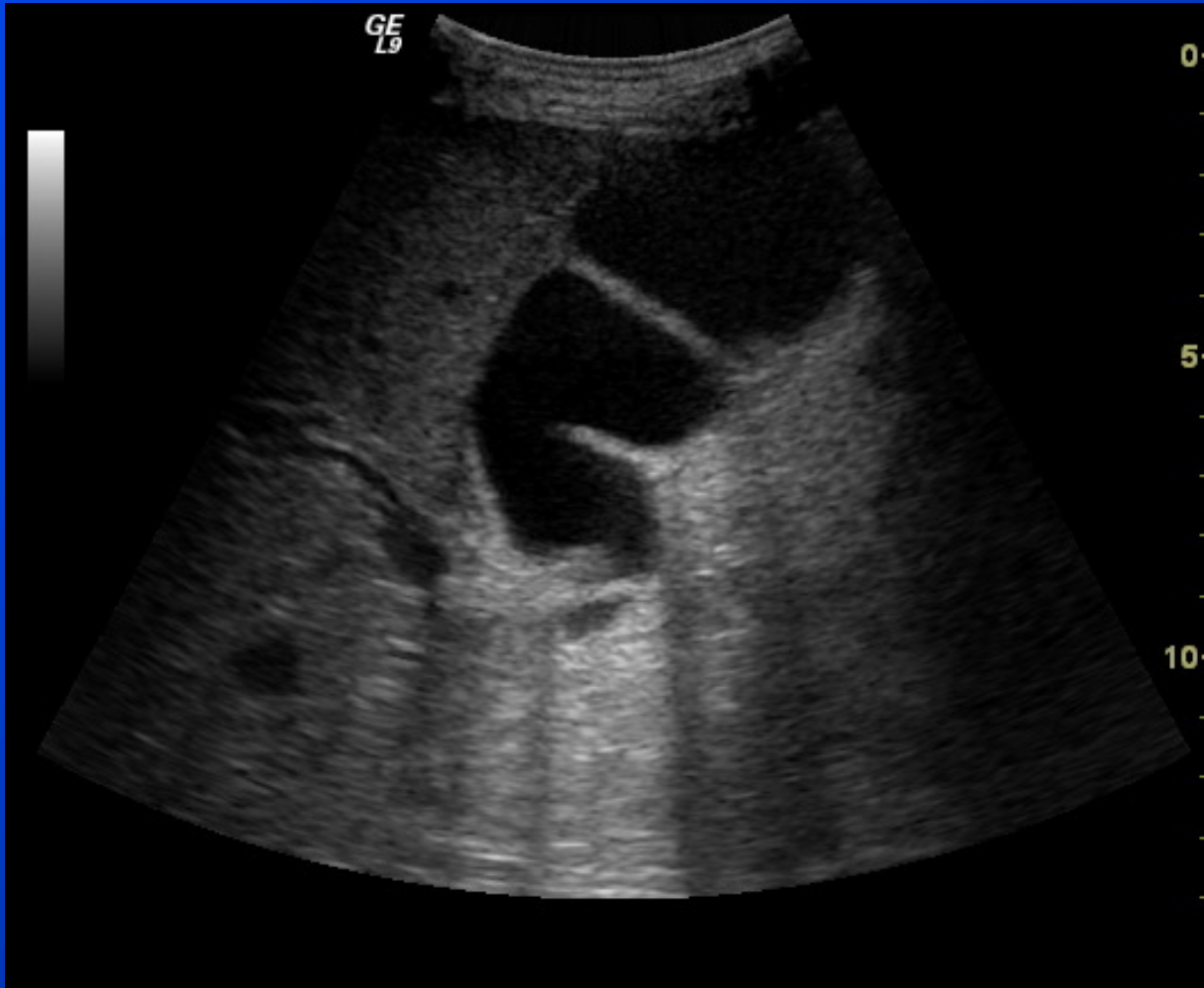


Normal Wall Thickness



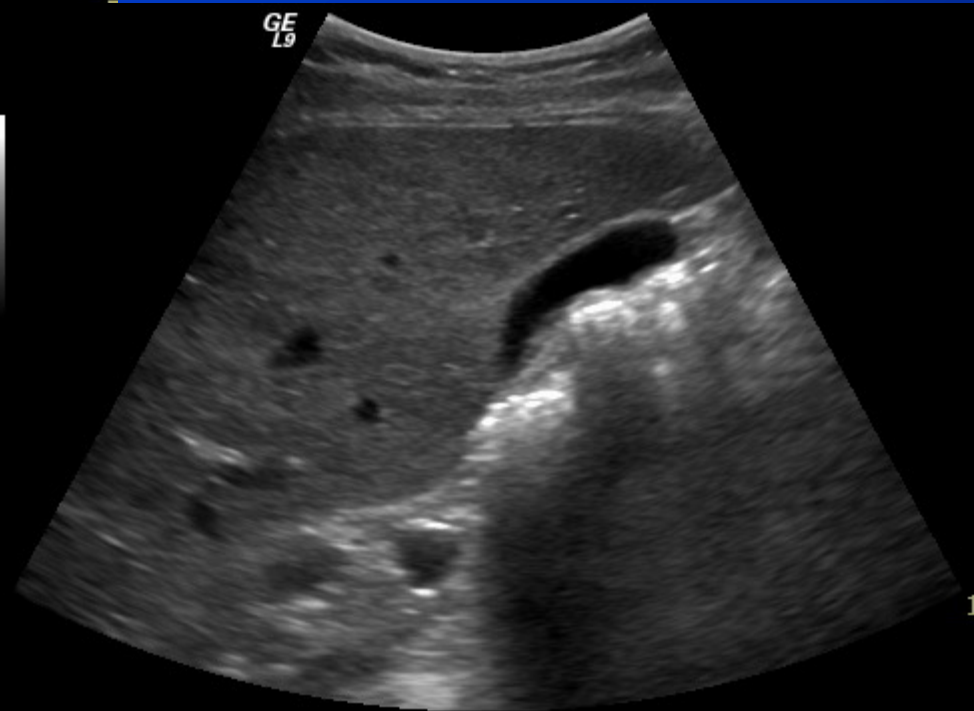
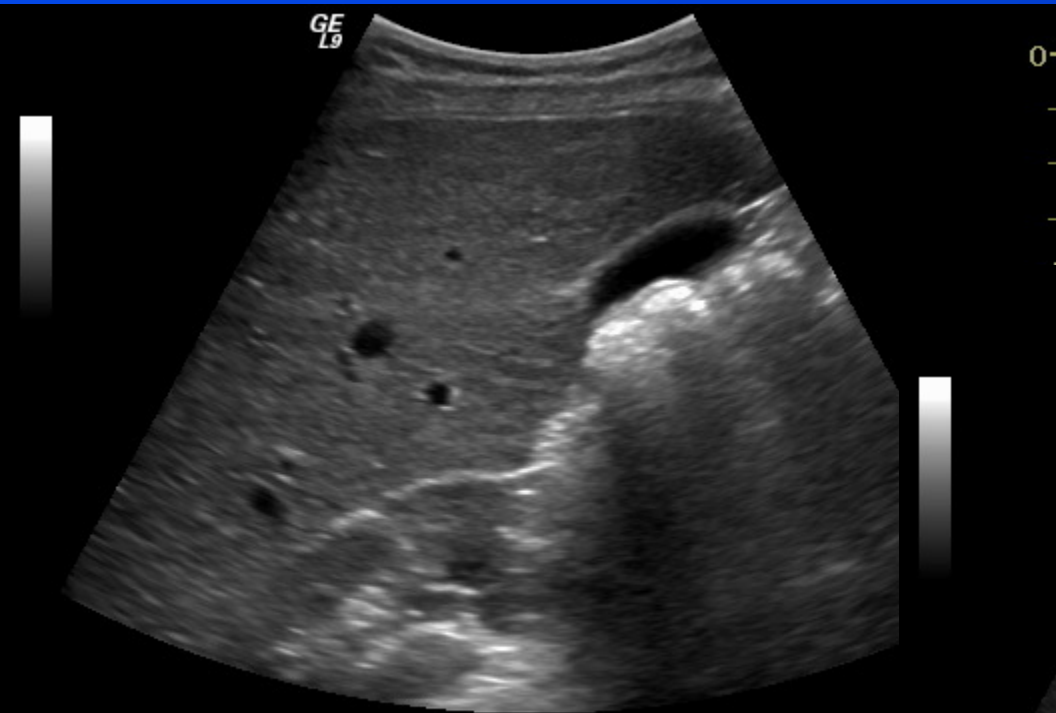


Folded Gallbladder





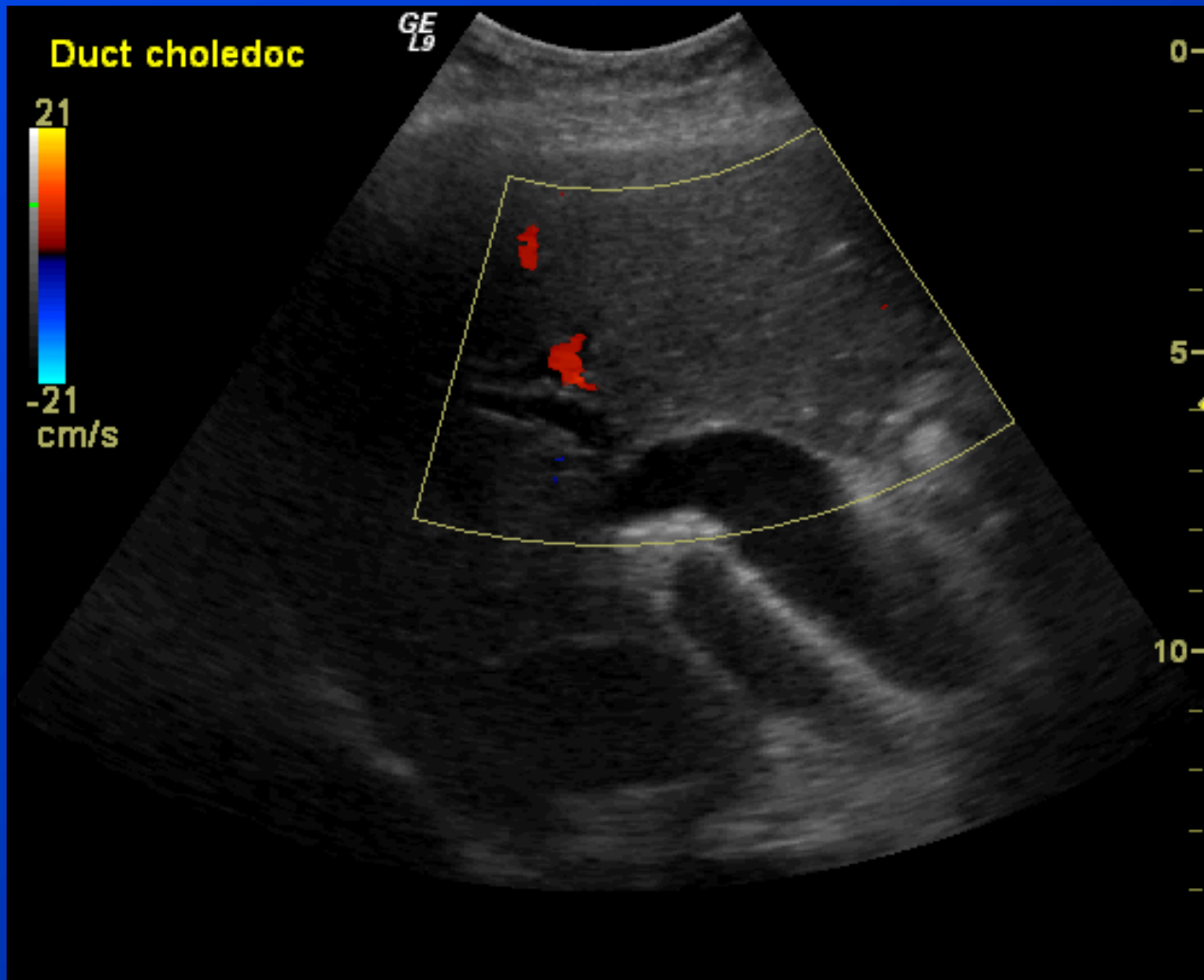
Air in the Duodenum, not stone



Comet tail artifact



Biliary Tract – Use color Doppler!





Normal Measures for the Gallbladder

- Wall thickness 2-3 mm
 - Cut-off pathology: 4 mm
- (Length 8-10 cm)
- Diameter 4 cm

Wall thickening is an unspecific sign



Sludge

Haukeland US
03/27/10 12:29:14 ADM

MI 1.0 TIs 1.7 C1-5
GASTI

Haukeland US
03/27/10 12:33:22 ADM

MI 1.0 TIs 1.7 C1-5
GASTRO

LOGIQ E9

CHI
Frq
0-Gn
S/A
-Map
D
-DR
-AO%

LOGIQ E9

CHI
Frq 4.0
0-Gn 73
S/A 1/1
-Map F/1
D 12.0
-DR 66
-AO% 100

Haukeland US
08/06/10 11:40:47 ADM

MI 0.5 TIs 0.5 9L

GASTRO

LOGIQ E9

CHI
Frq 8.4
-Gn 4.1
S/A 3/1
-Map F/1
D 10.0
-DR 63
-AO% 100

5-

10-

5-

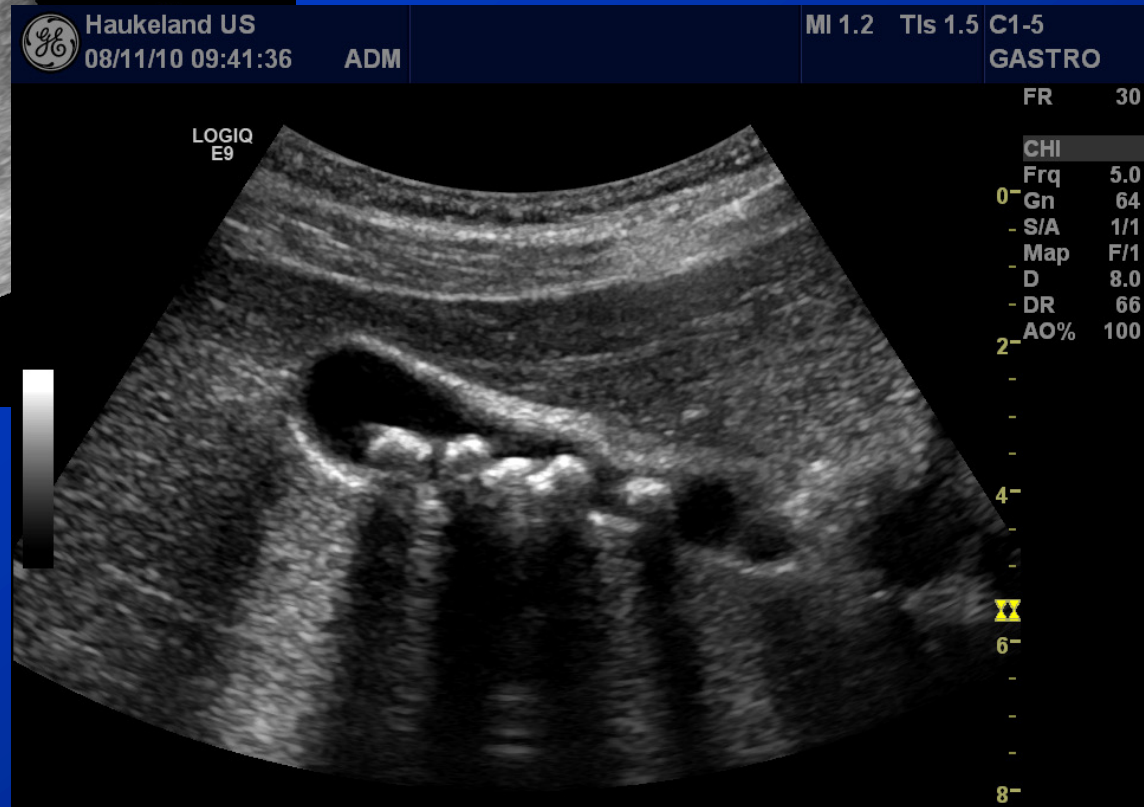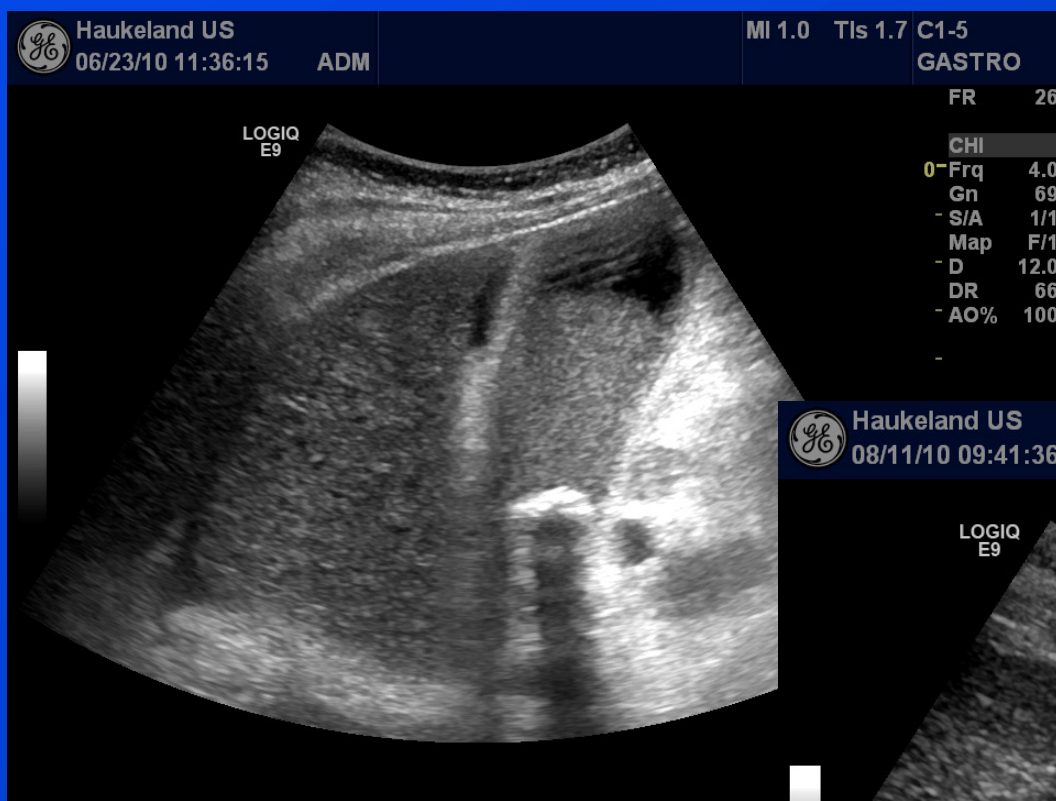
10-

5-

10-

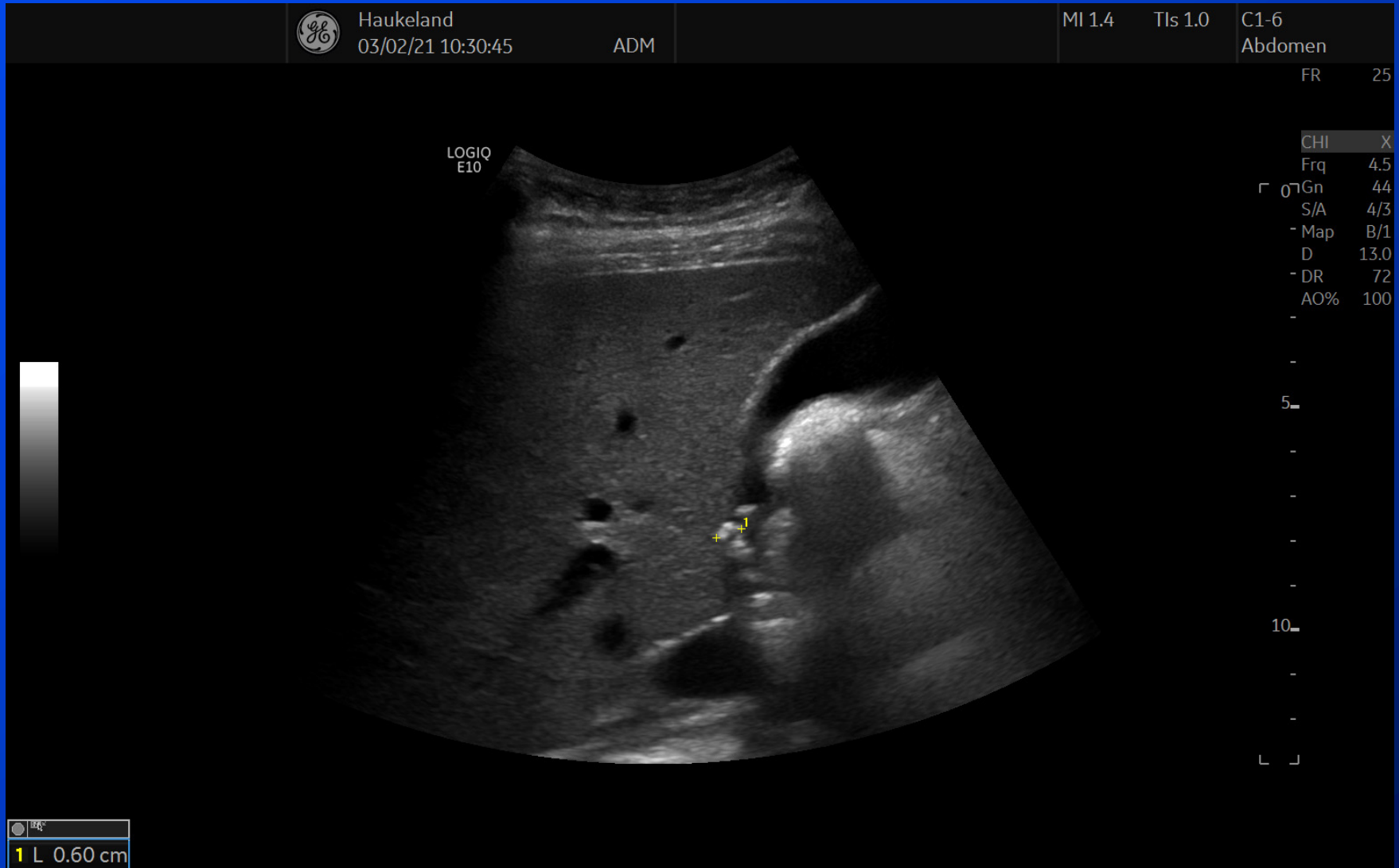

Gallbladder stone



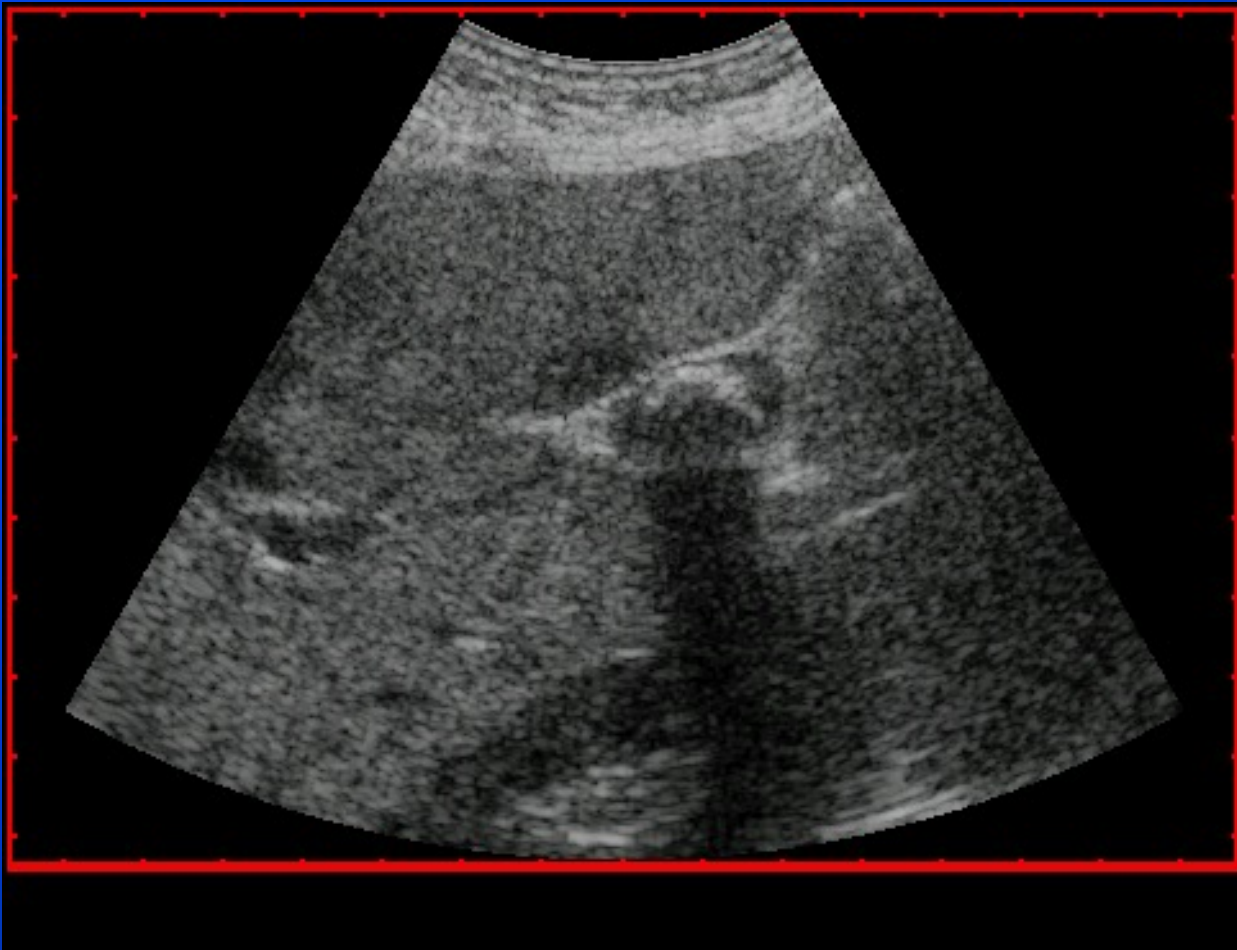


Gallbladder stone,- where?



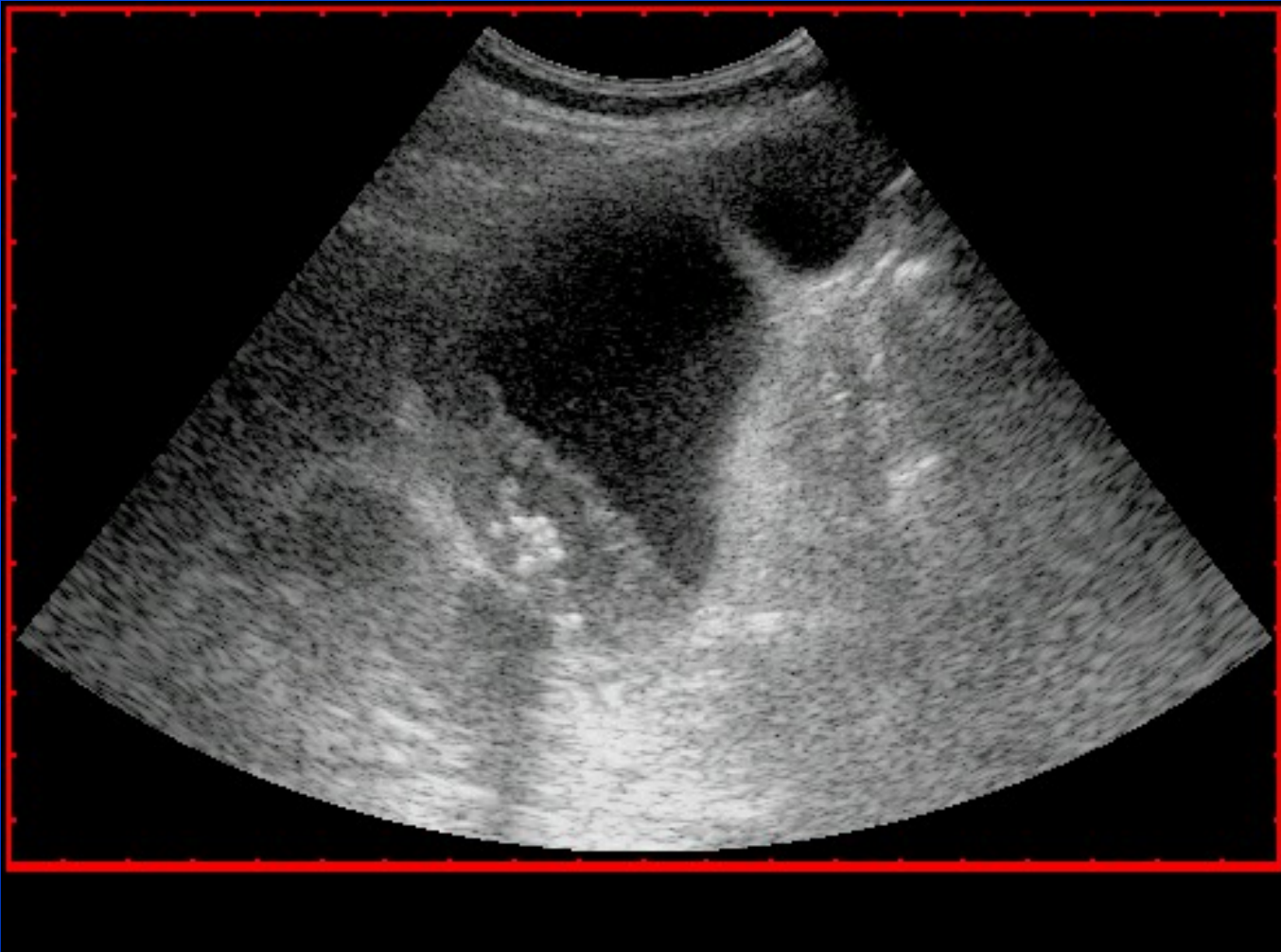


Small Gallbladder – big stone



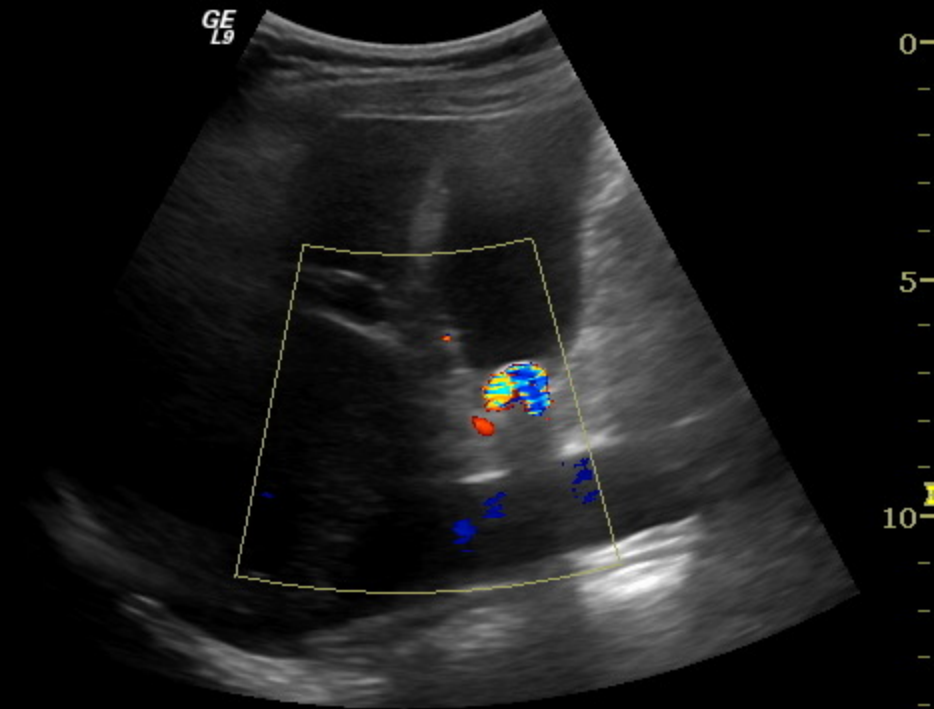
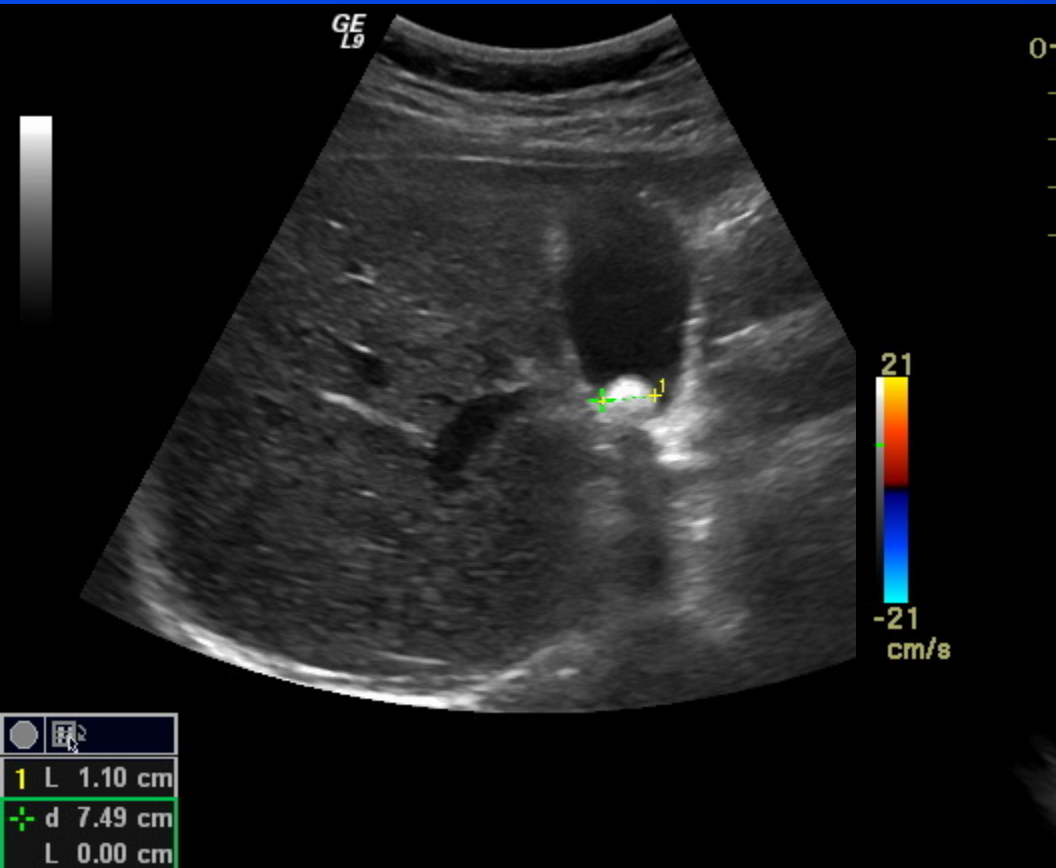


Galleblæresteiner og Grus



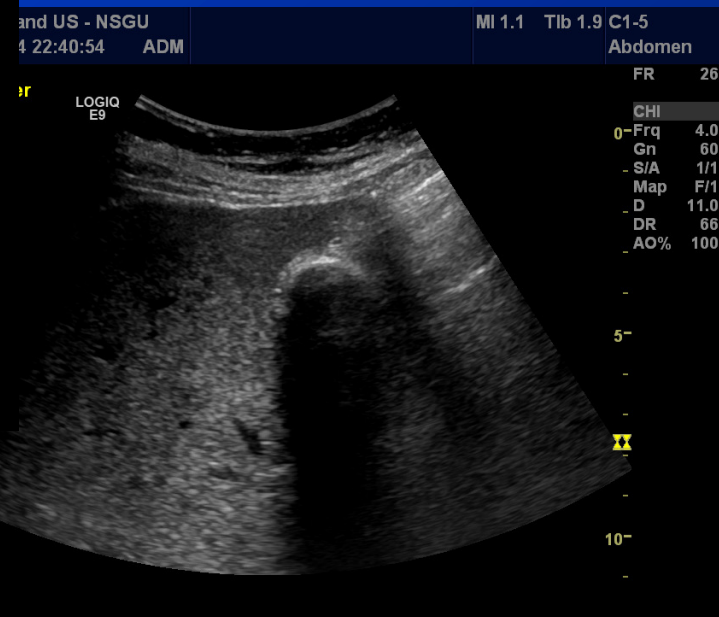
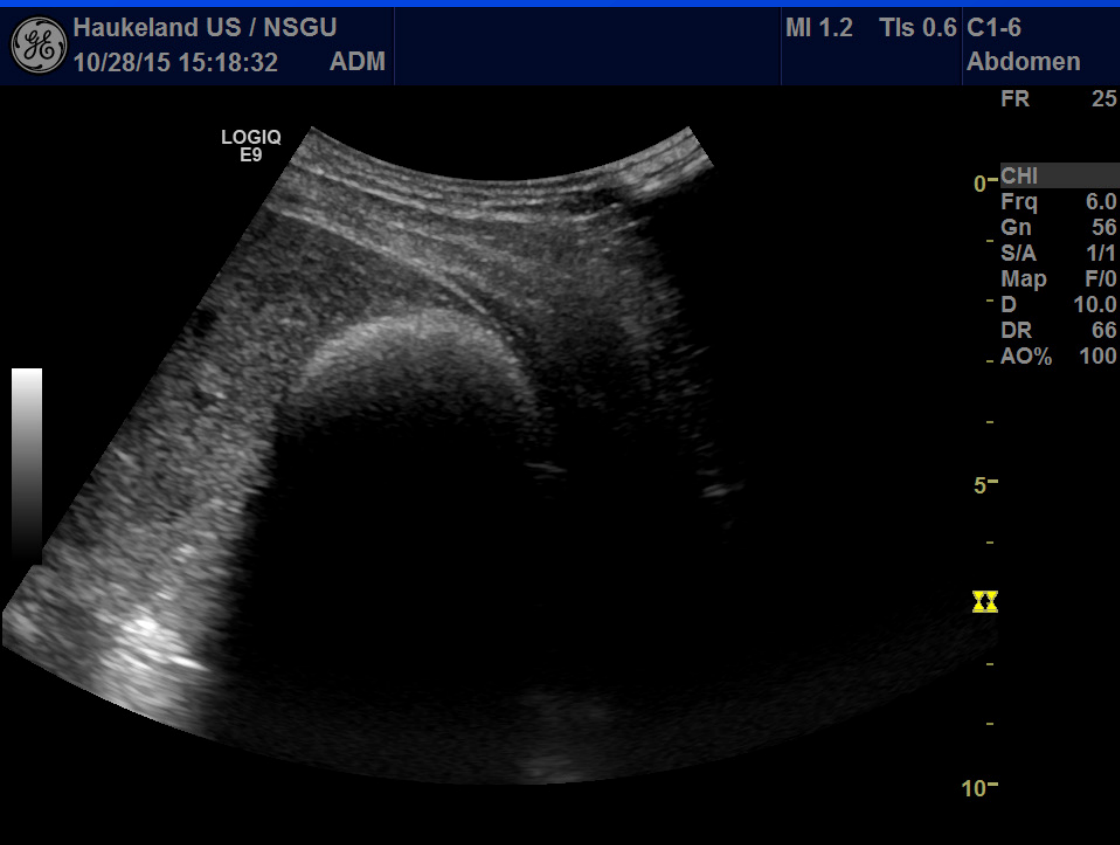


Twinkling Artifact





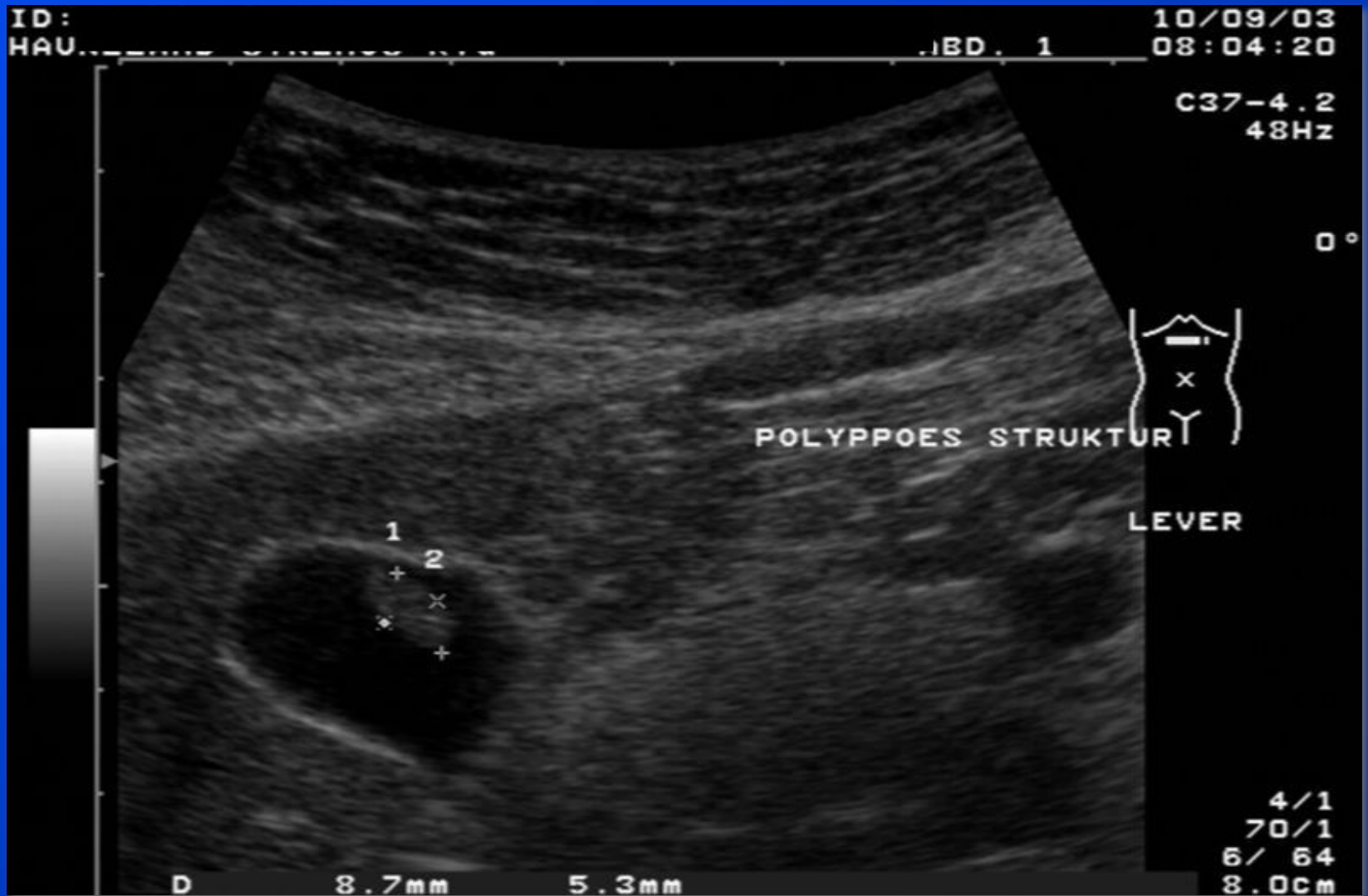
Porcelain Gallbladder





POLYPS

- Small, echogenic lesion adherent to the gallbladder wall
- Can be pedunculated, but most often not
- No shadow
- Sometimes only pseudopolyps
- Follow-up necessary if $> 6\text{mm}$
- Surgery if $> 10\text{mm}$

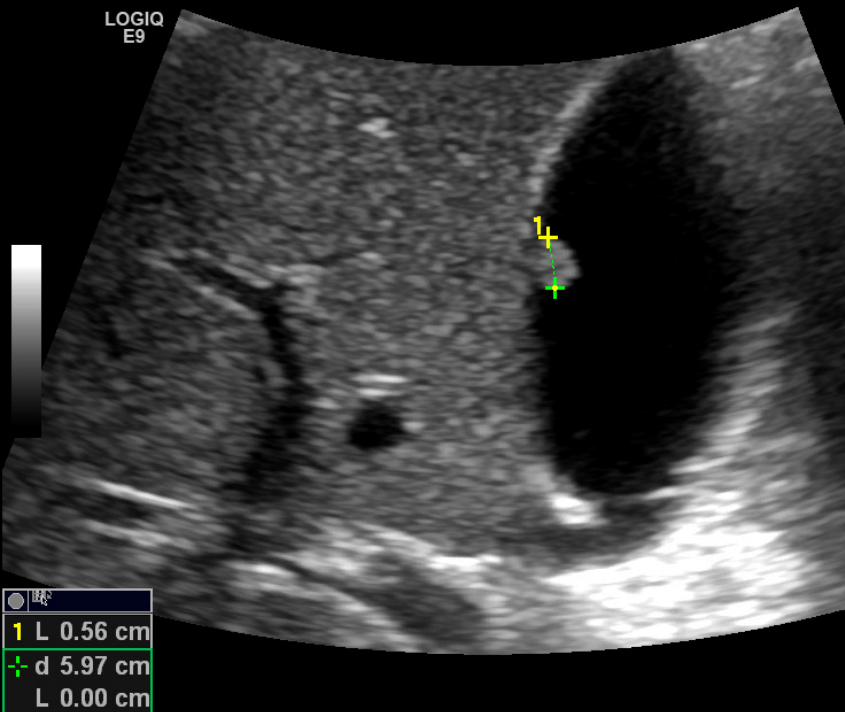




Galbladder Polyps

GE Haukeland US 09/29/10 10:45:48 ADM MI 1.2 TIs 1.9 C1-5 GASTRO

| | |
|-----|-----|
| FR | 26 |
| CHI | |
| Frq | 4.0 |



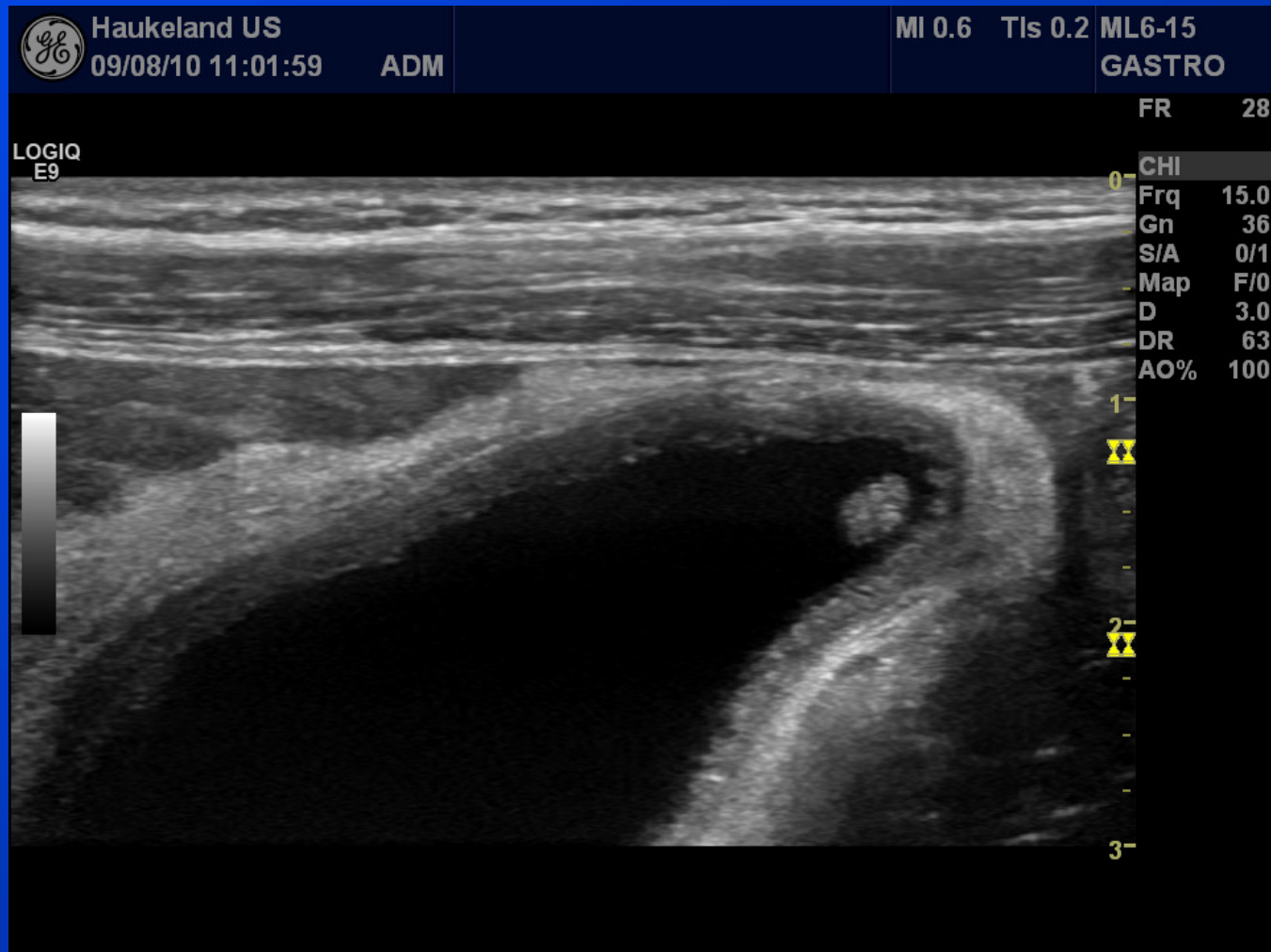1 L 0.56 cm
+ d 5.97 cm
L 0.00 cm

GE Haukeland US 09/29/10 10:46:27 ADM MI 1.2 TIs 1.5 C1-5 GASTRO

| | |
|-----|------|
| FR | 15 |
| CHI | |
| Frq | 4.0 |
| Gn | 64 |
| D | 10.0 |
| AO% | 100 |
| CF | |
| Frq | 3.6 |
| Gn | 20.0 |
| L/A | 0/7 |
| PRF | 1.9 |
| WF | 140 |
| S/P | 5/12 |
| AO% | 100 |

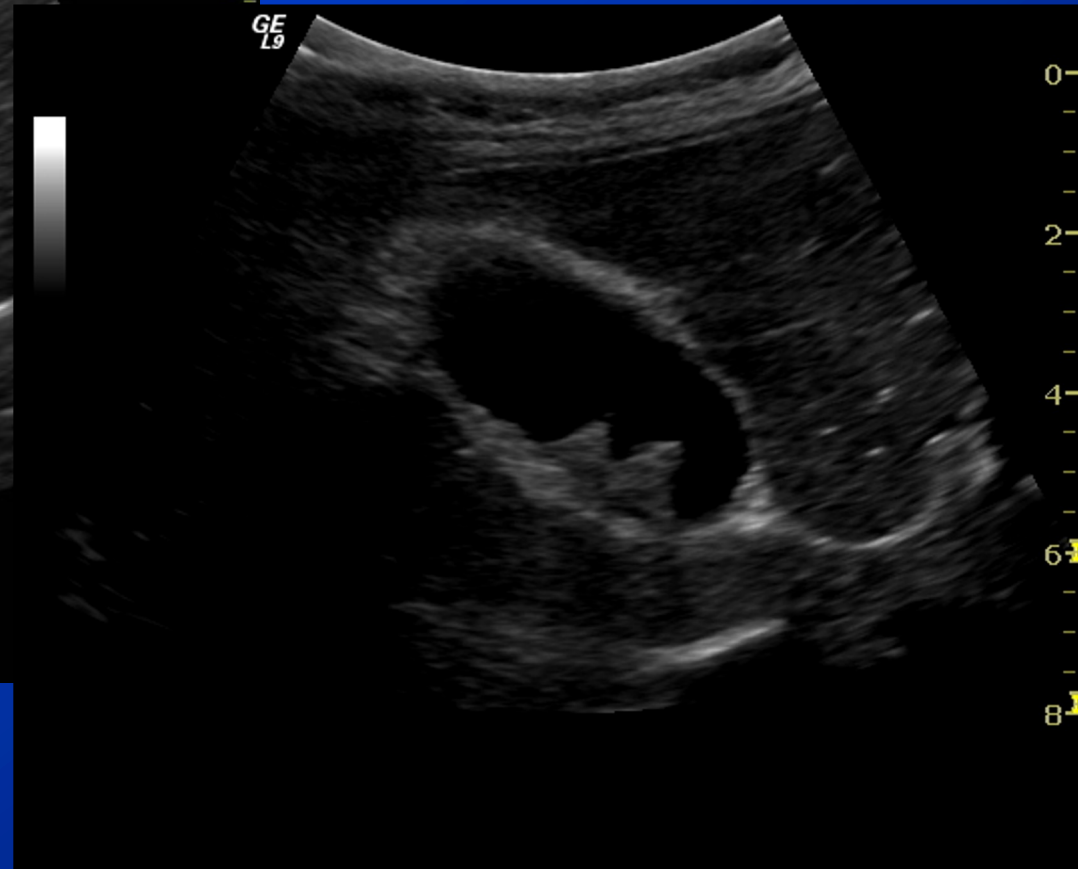
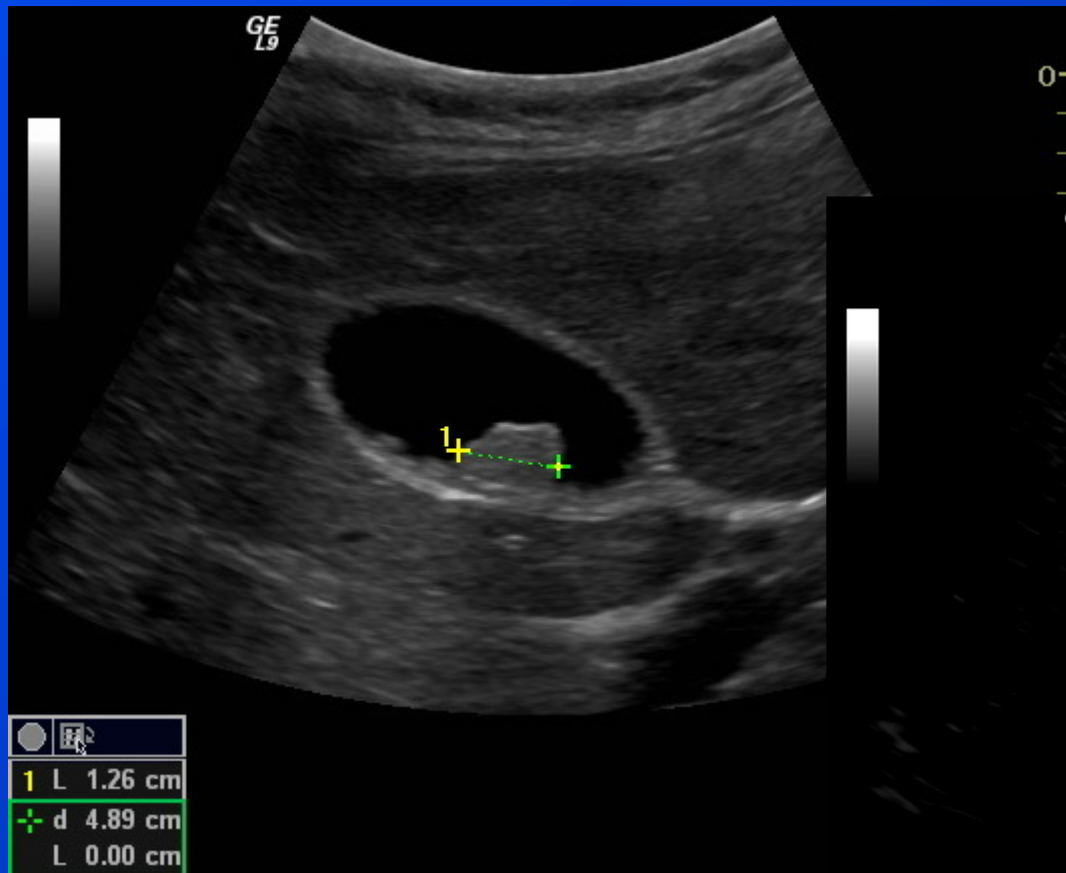


Small Polyp



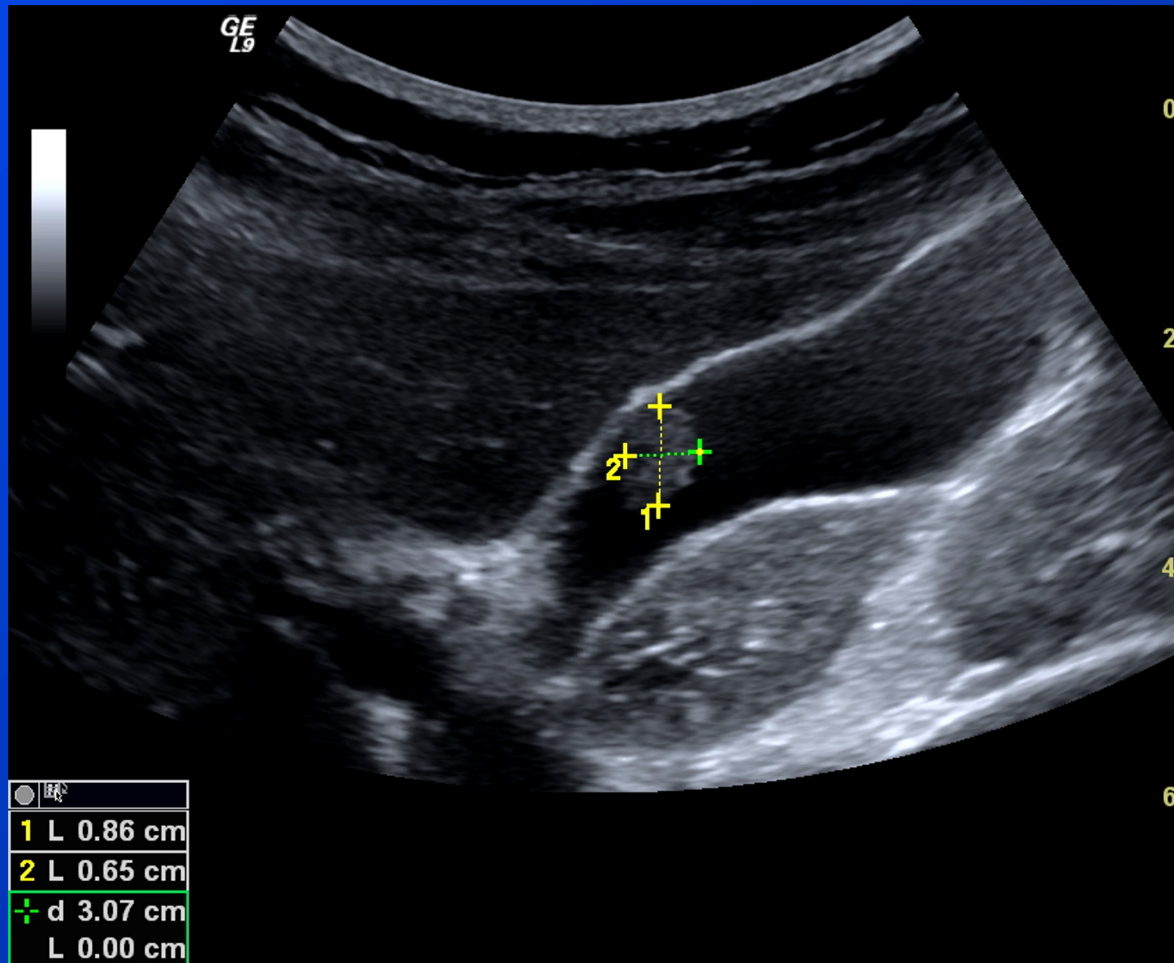


Gallbladder tumor





Gallbladder tumor





Tumor of the gallbladder wall



Haukeland
09/02/22 15:06:13

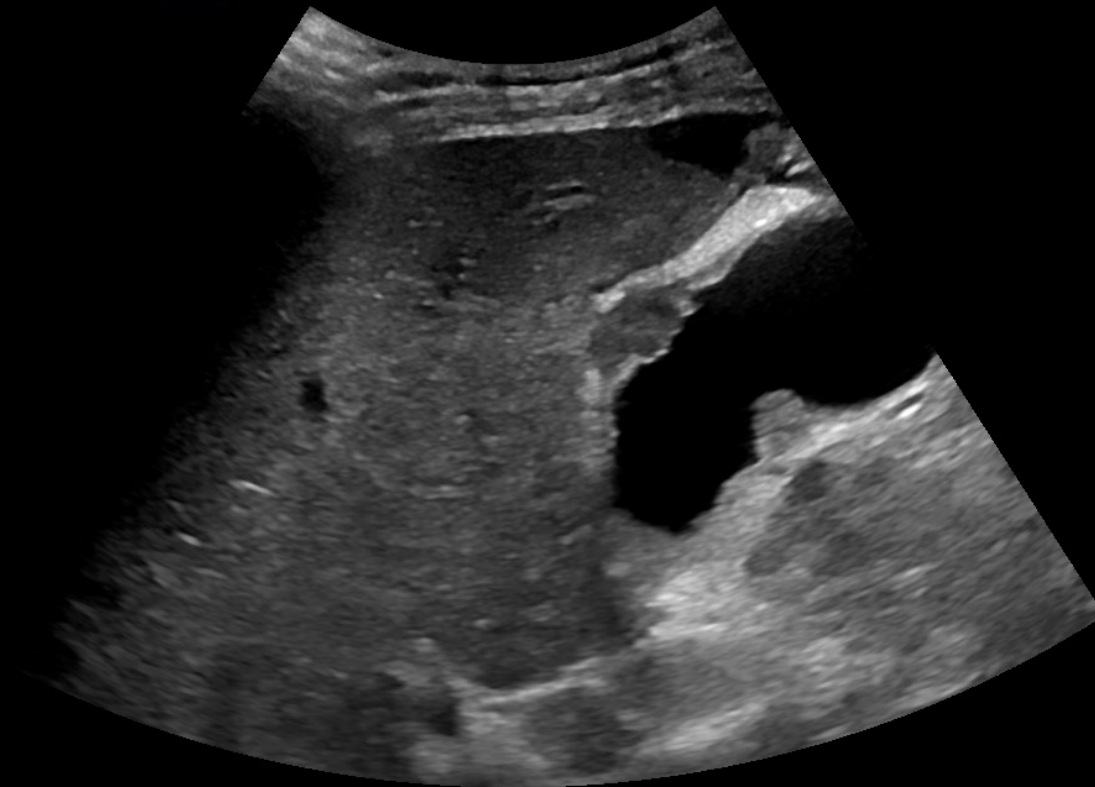ADM

MI 1.4 TIs 0.3

C1-6
AbdDetail

FR 38

LOGIQ



| CHI | X |
|-----|------|
| Frq | 4.5 |
| Gn | 50 |
| S/A | 4/2 |
| Map | D/2 |
| D | 11.0 |
| Zm | 0 |
| DR | 66 |
| AO% | 100 |

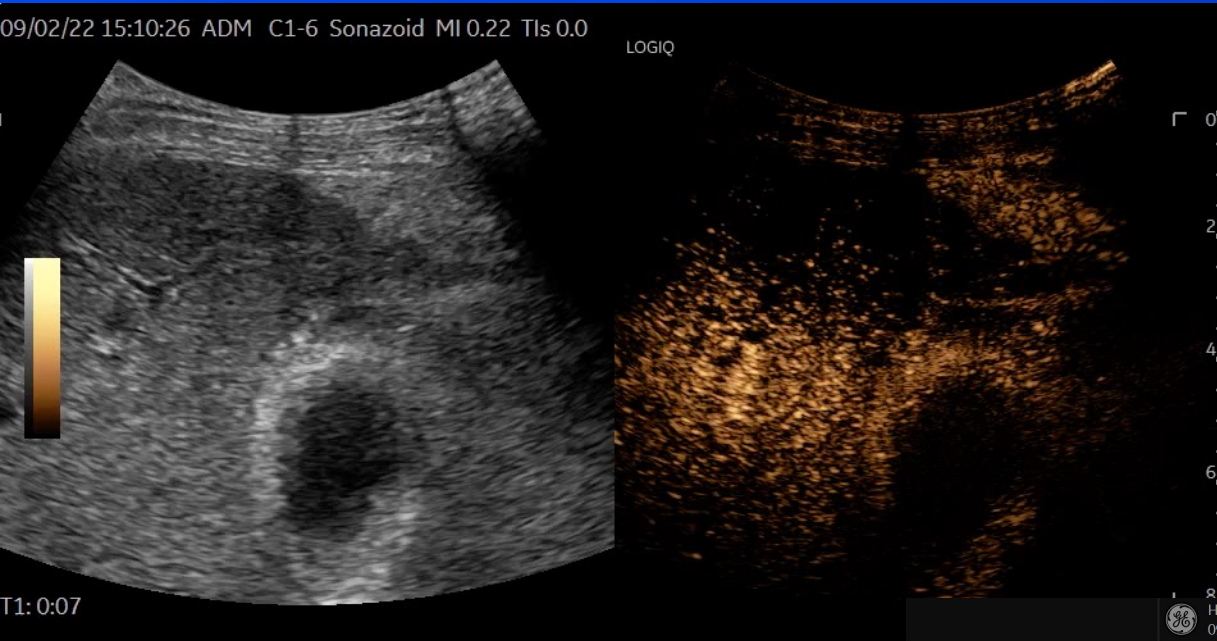
5

10

L

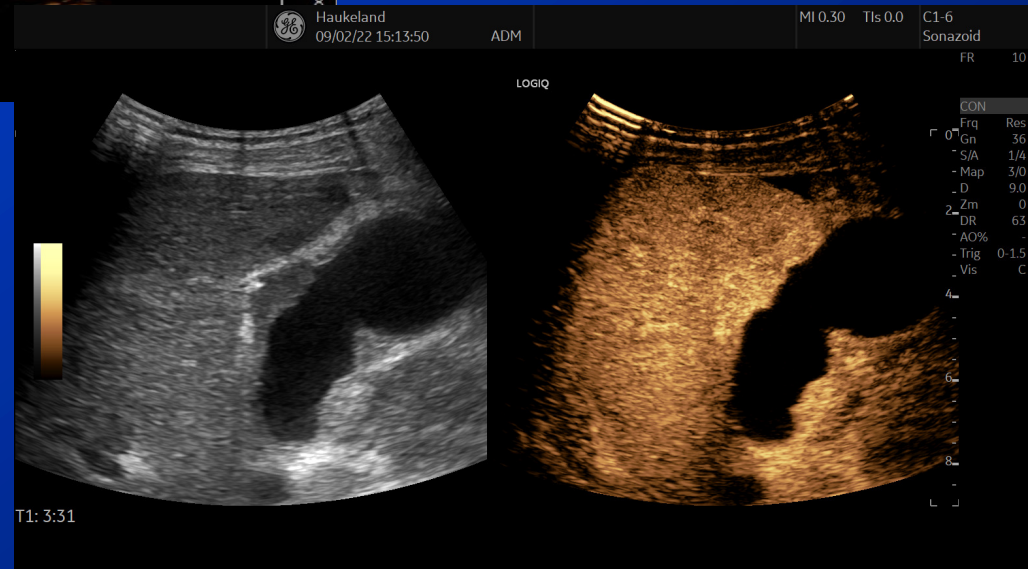


CEUS of Gallbladder tumor



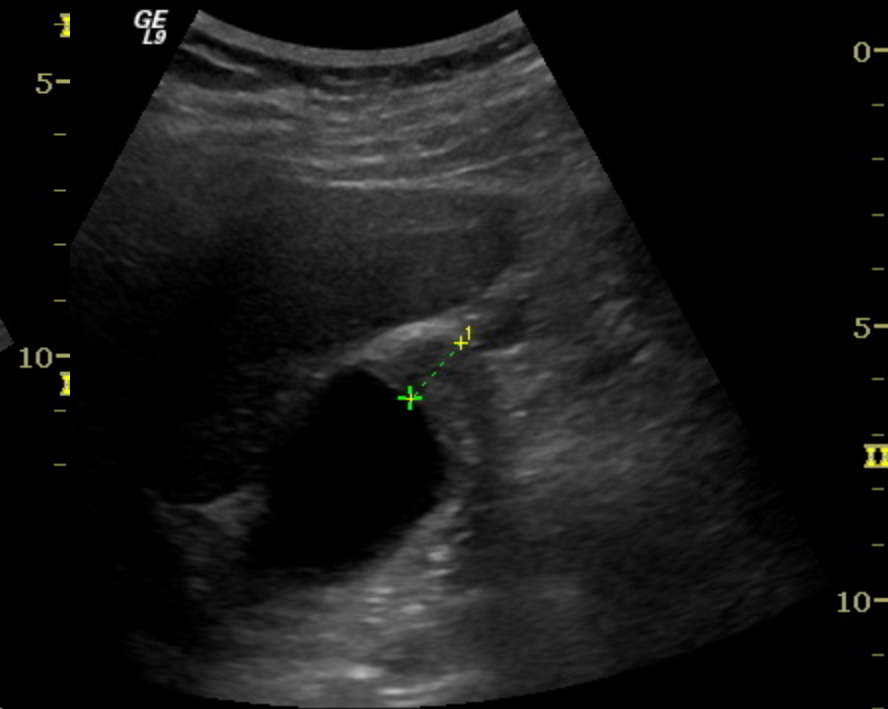
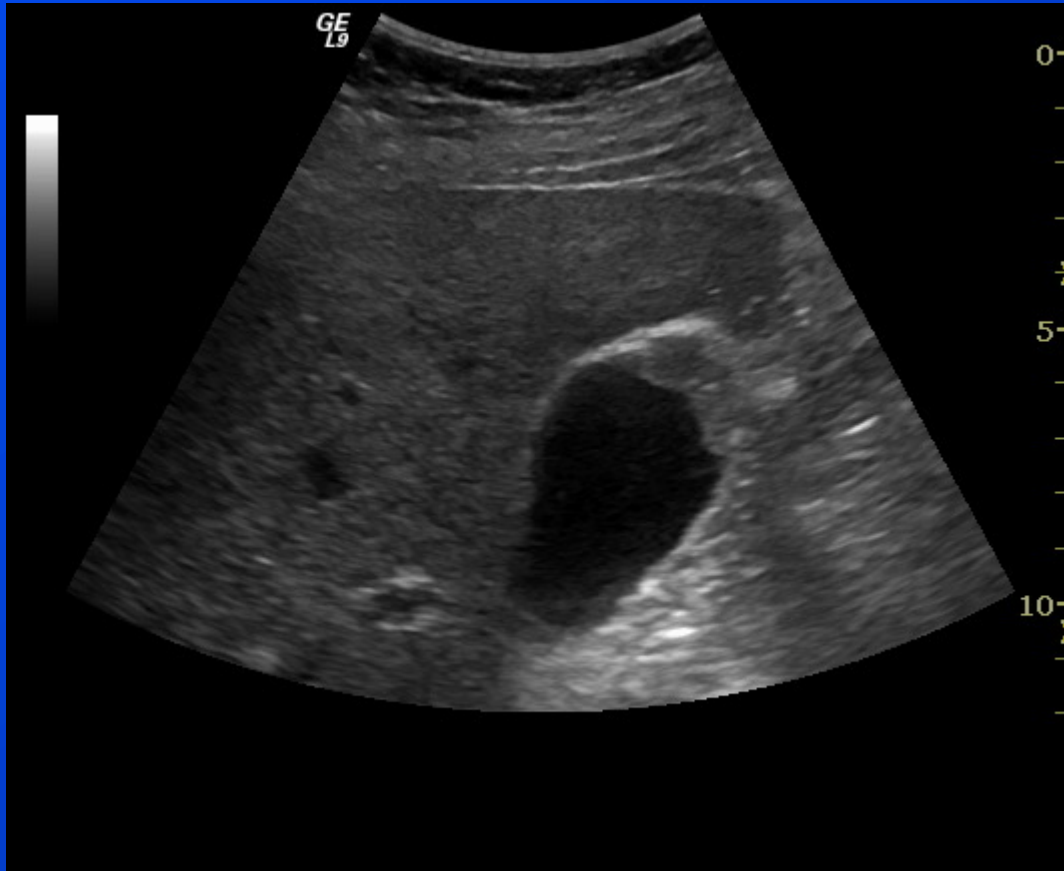
Sinusoidal phase

Arterial phase





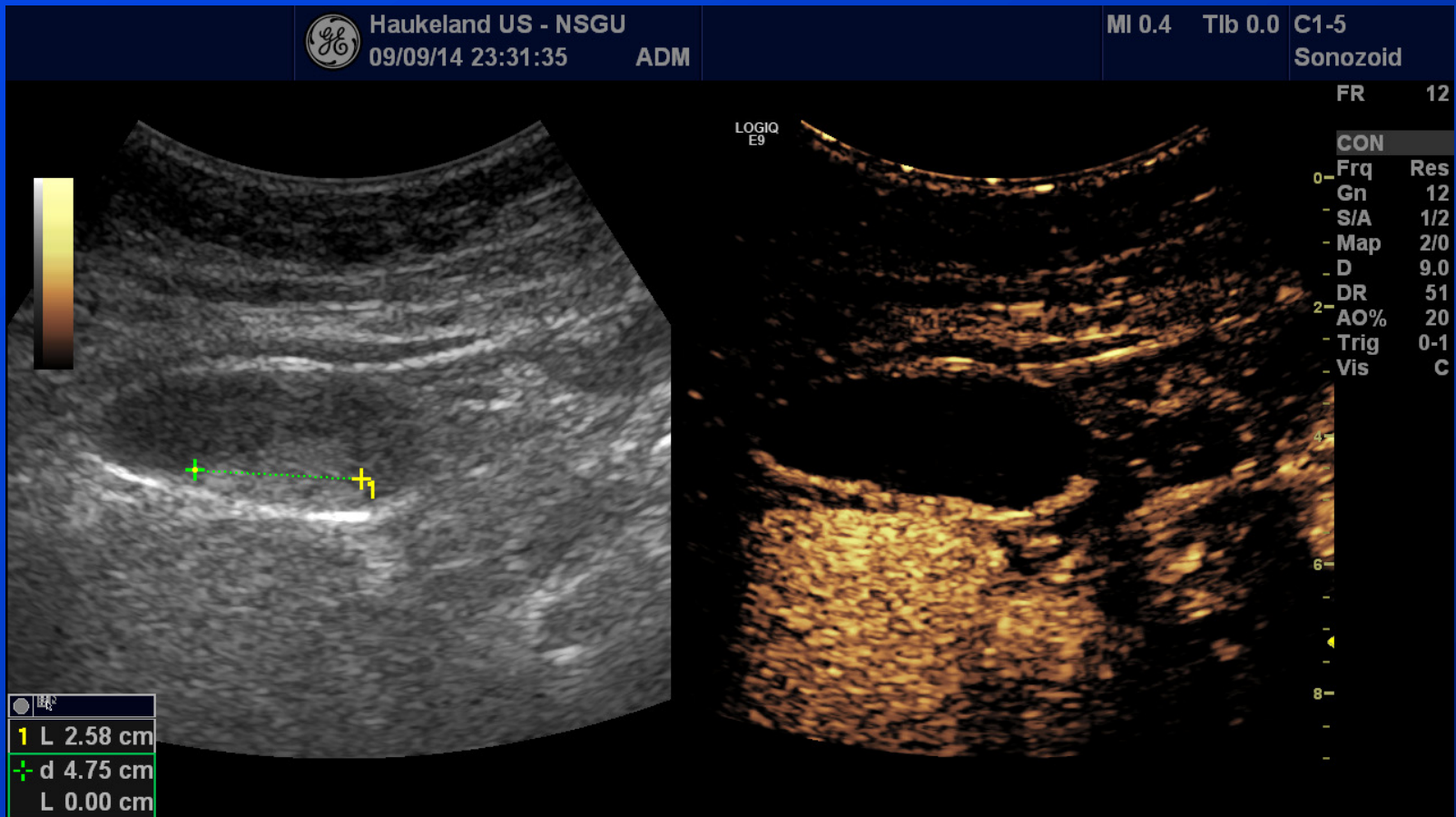
Cancer of the Gallbladder



| | | |
|---|---|---------|
| ● | ■ | □ |
| 1 | L | 1.36 cm |
| + | d | 6.38 cm |
| | L | 0.00 cm |



Gallbladder – Sludge or tumor?

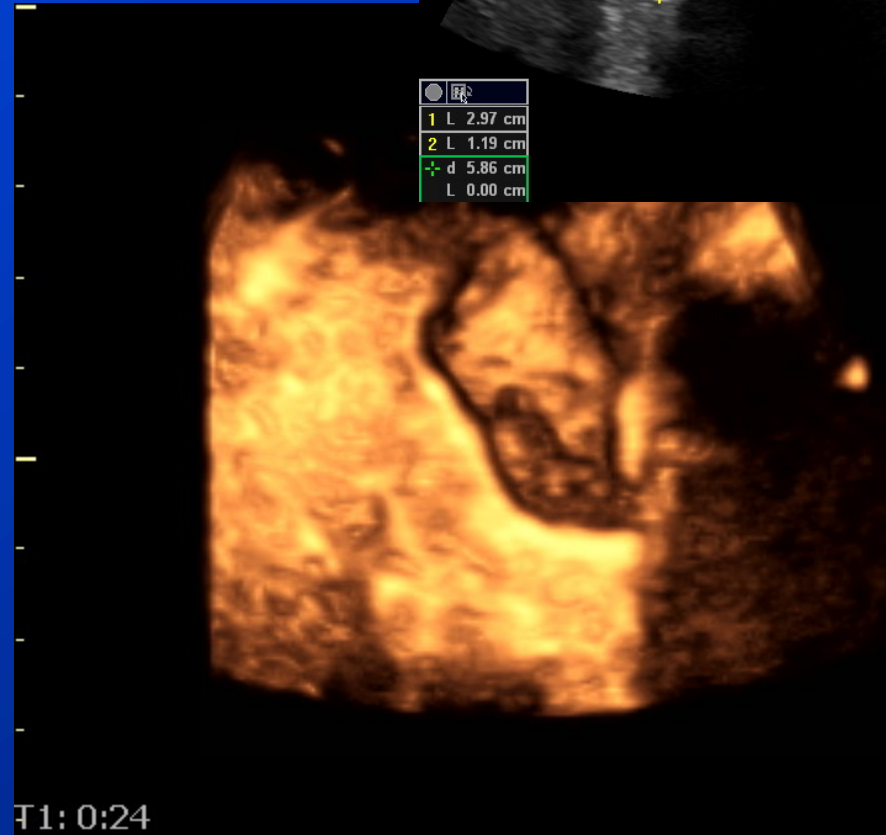
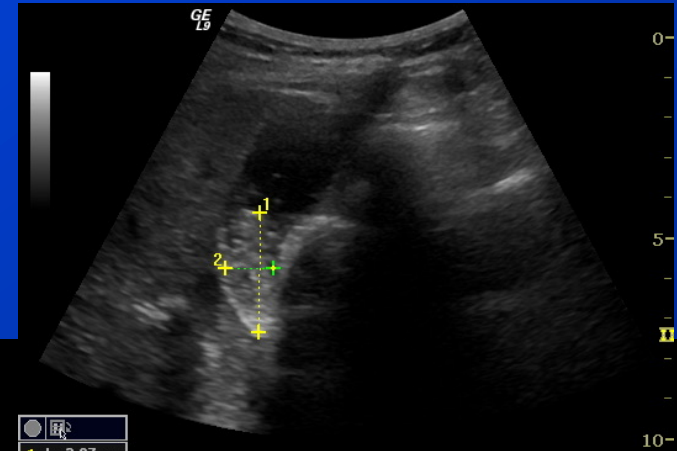




Gallbladder Adenomyomatosis

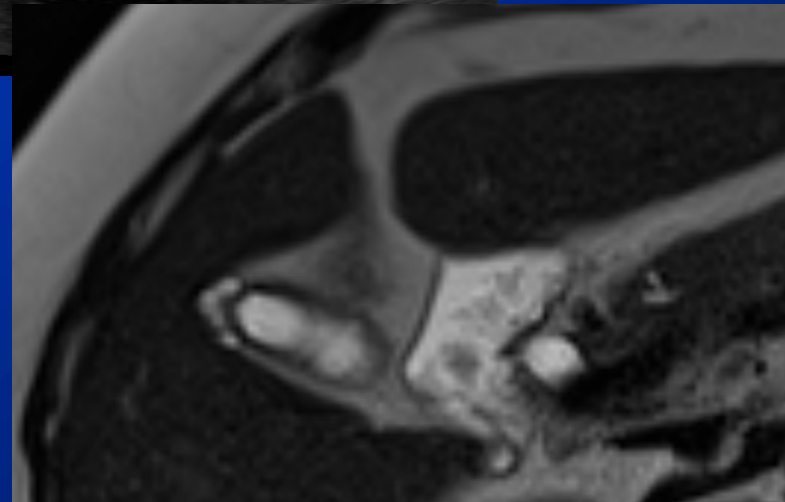
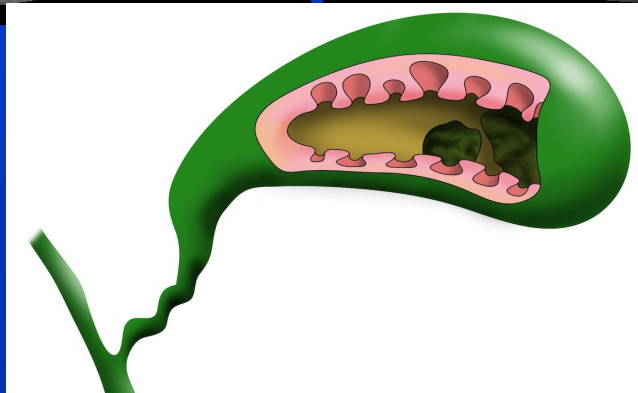
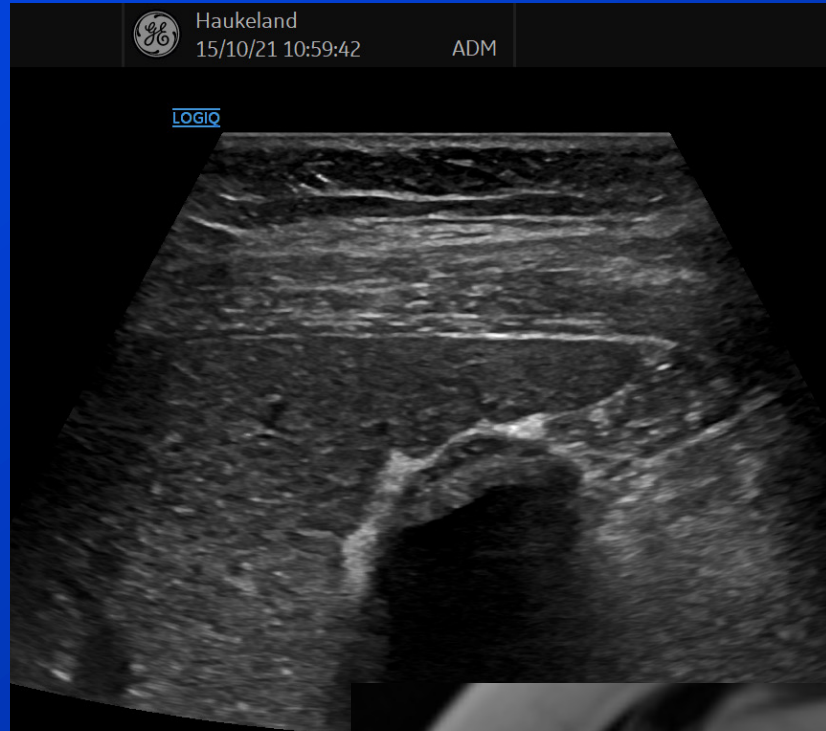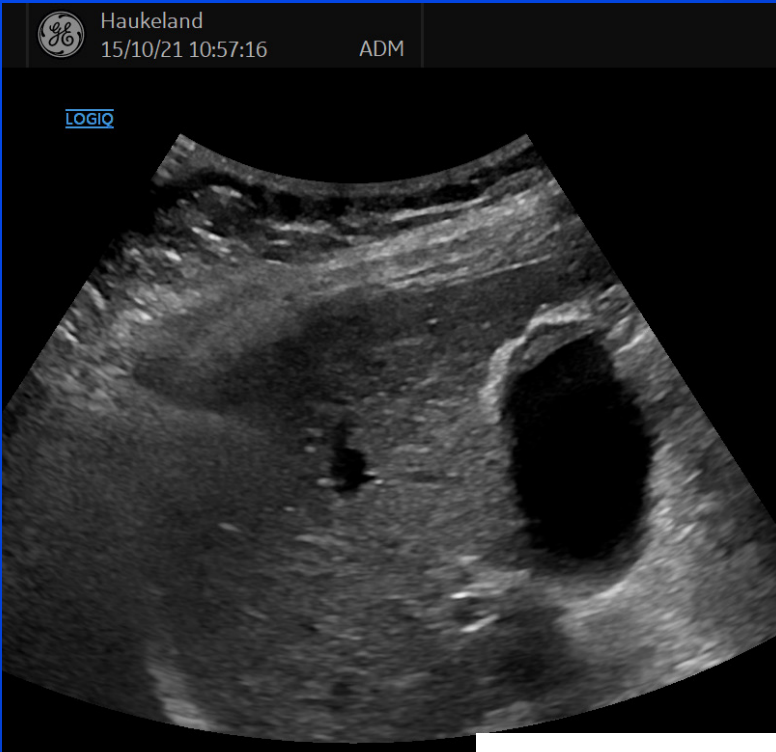
- 5 - 9% in cholecystectomy specimens
- No malignant transformation
- No treatment necessary

- Focal or diffuse thickening
- Rokitansky-Aschoff sinuses
 - Epithelial-lined intramural diverticles
 - Filled with mucin and cholesterolprecipitate



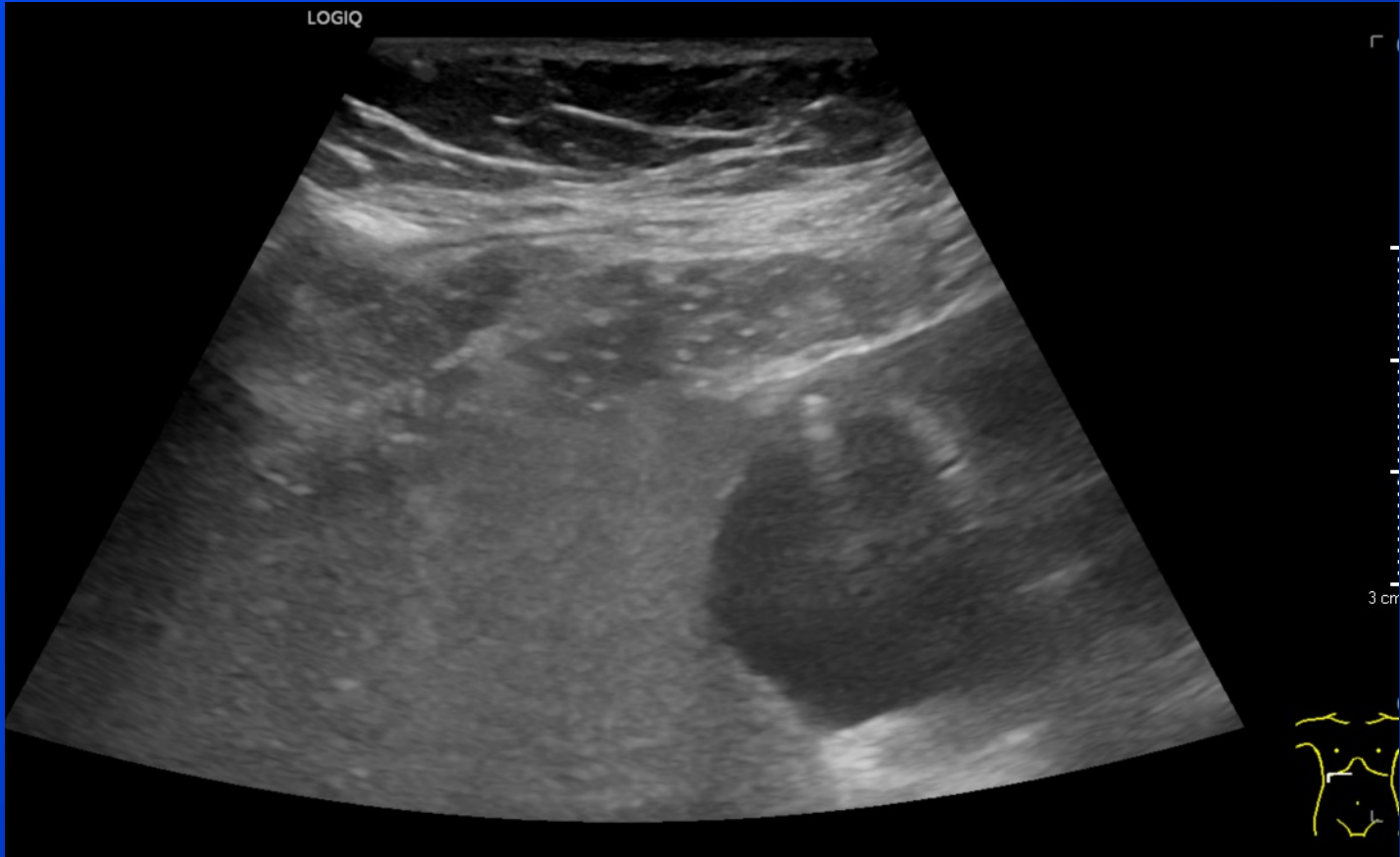


Adenomyomatosis of the Gallbladder





Adenomyomatosis



● **Komethaleartefakt**

● **Cholesterolprecipitater i Rokitansky-Aschoff sinus**

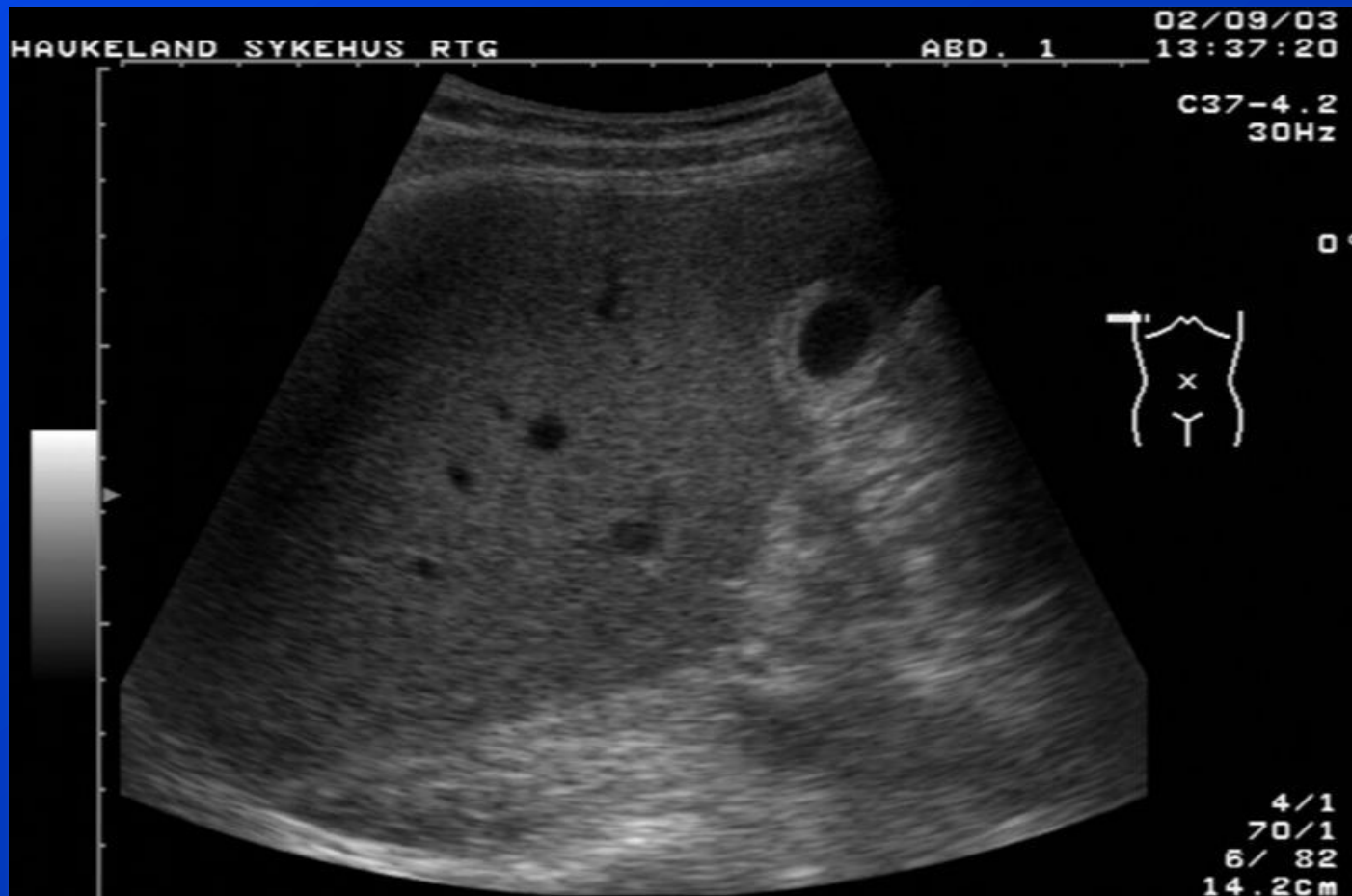

Wall Thickening of Biliary System

- Gallbladder:
 - Postprandial contraction
 - Ascites
 - Cirrhosis / Portal hypertension
 - Heart failure / Kidney failure
 - Hypoalbuminemia
 - Hepatitis
 - Cholecystitis
 - Focal thickening in Polyps / neoplasia
- Biliary Ducts:
 - Primary Sclerosing Cholangitis
 - Cholangiocarcinoma

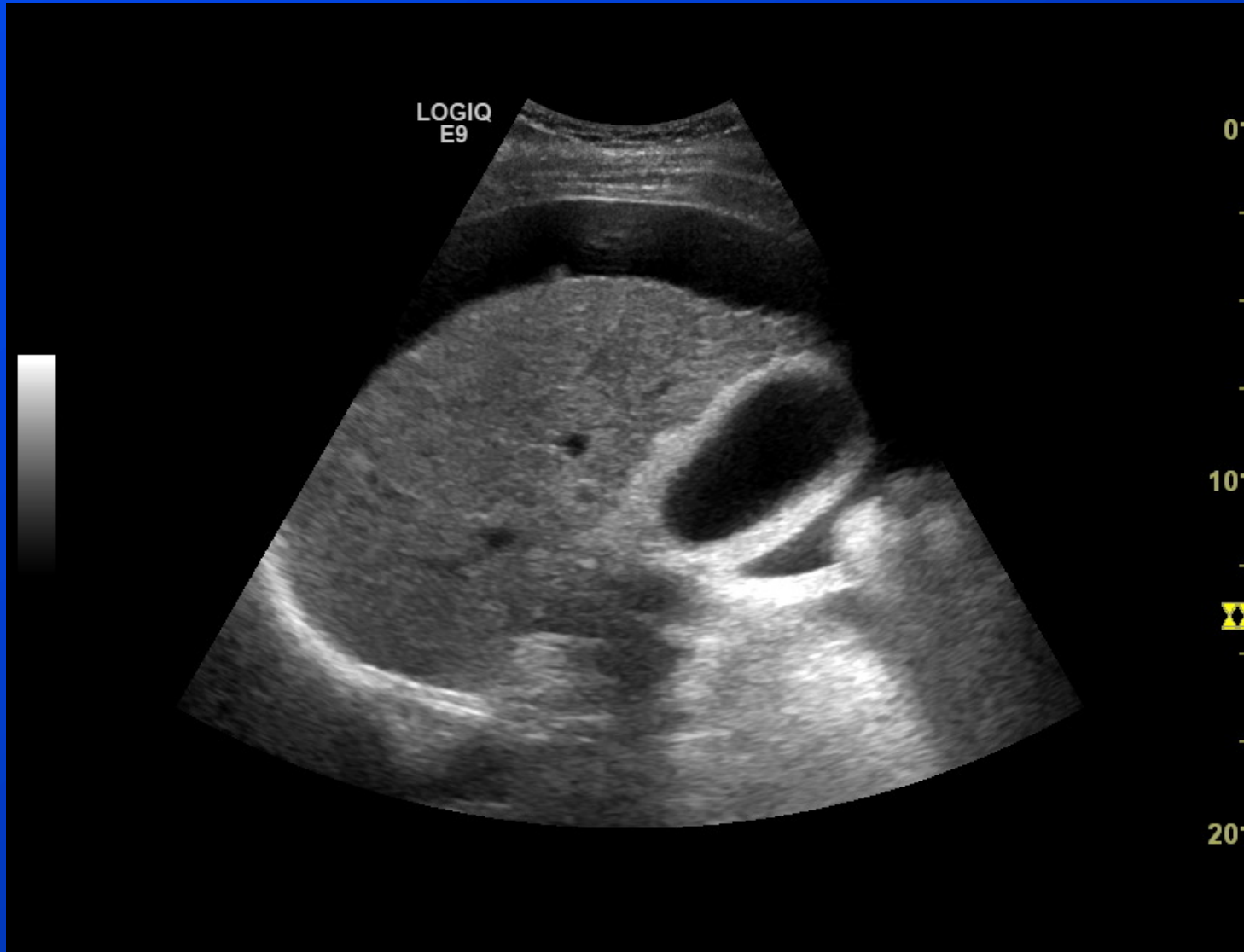


Non-Fasting Gallbladder



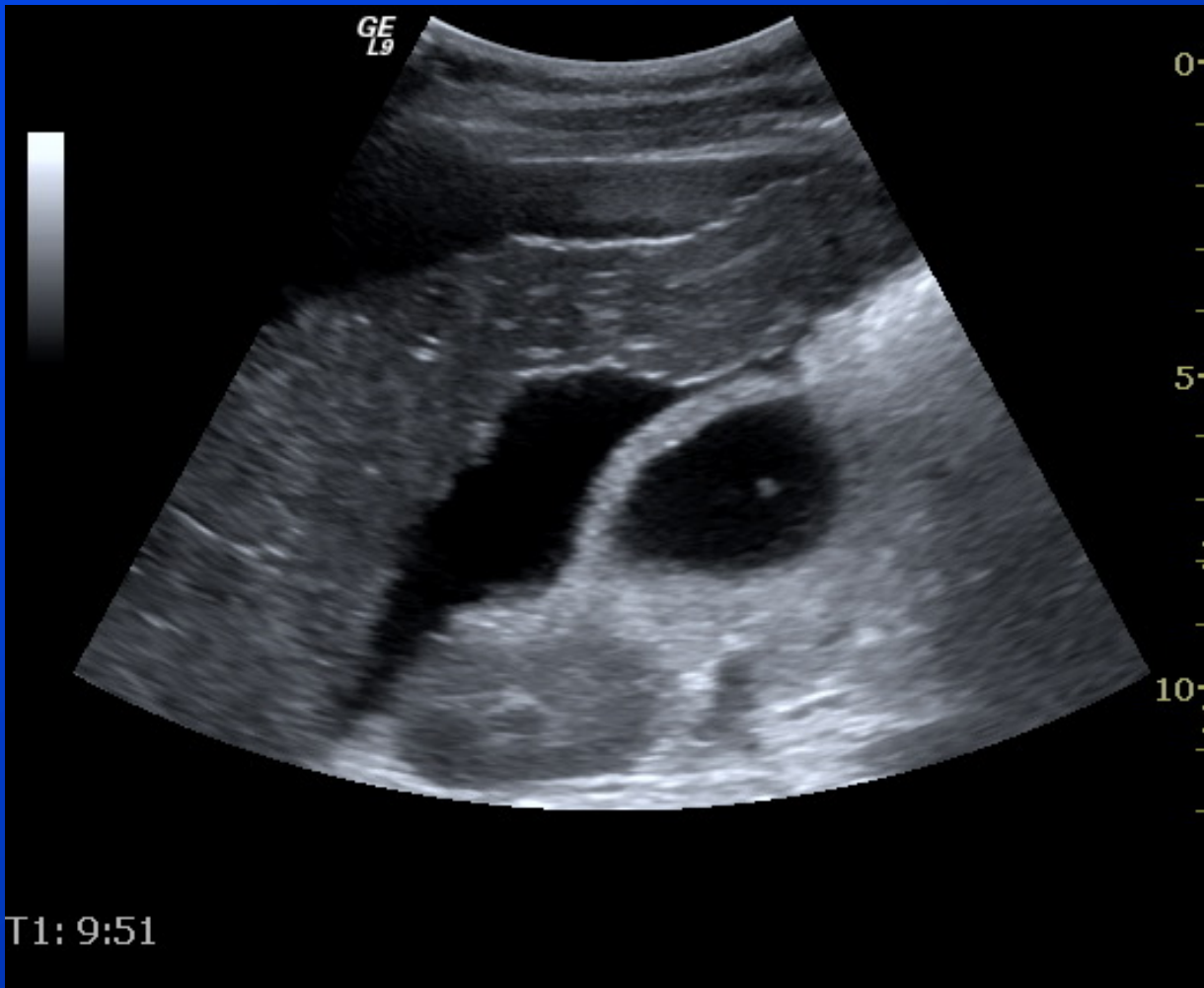


Thickened wall in ascites



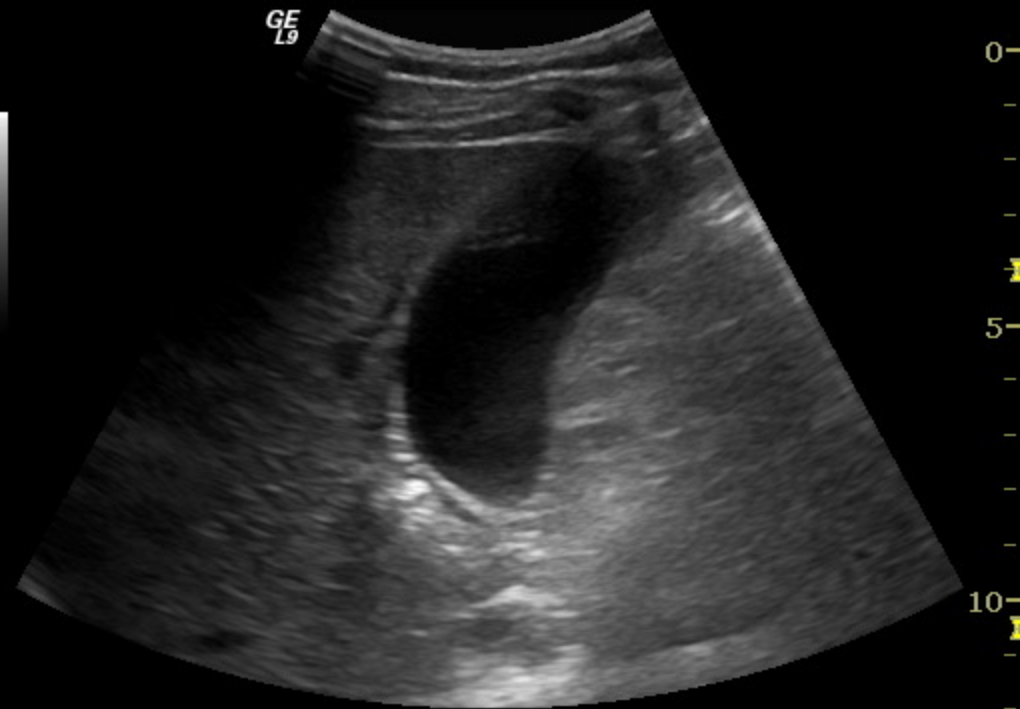
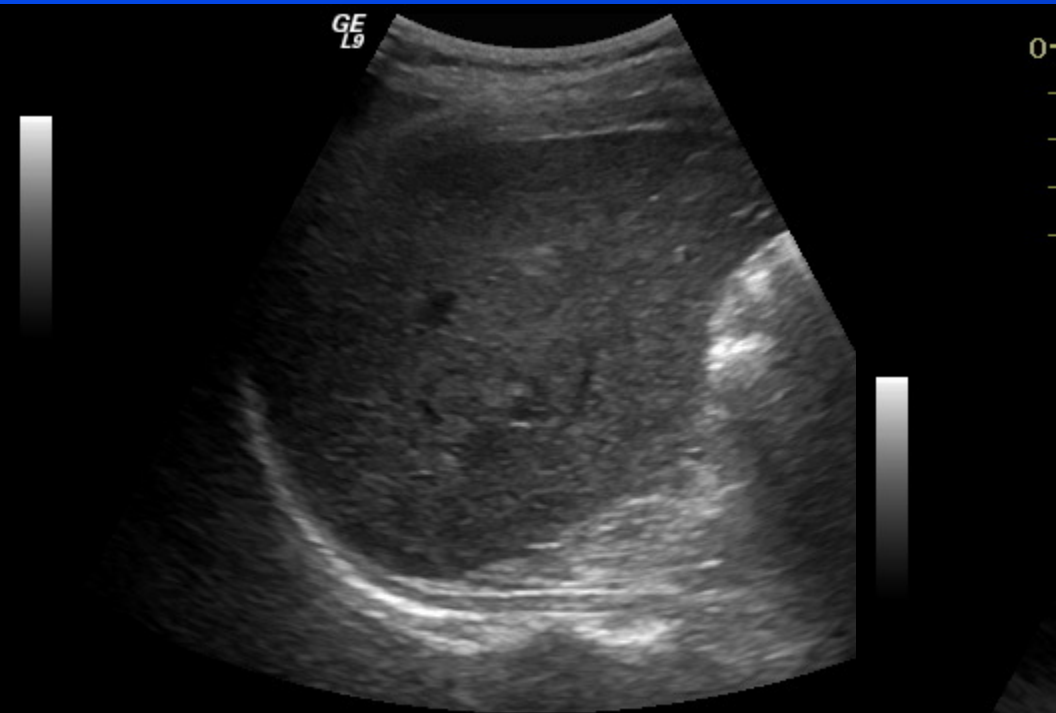


Cirrhosis



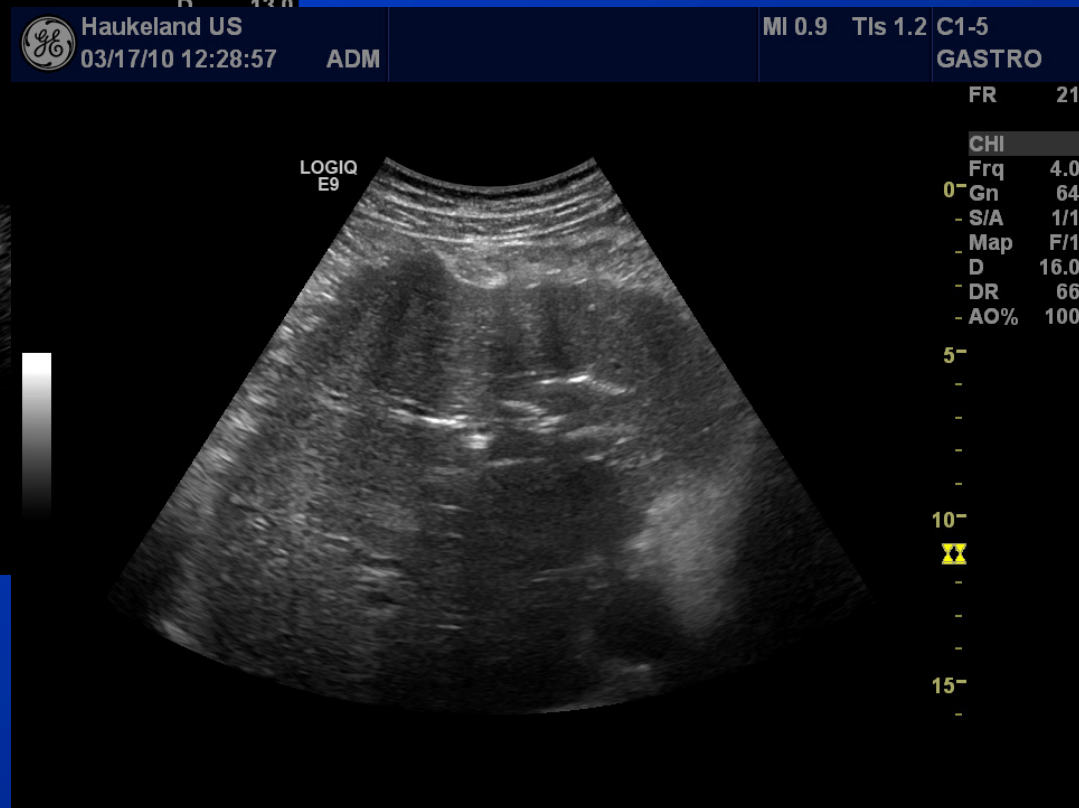
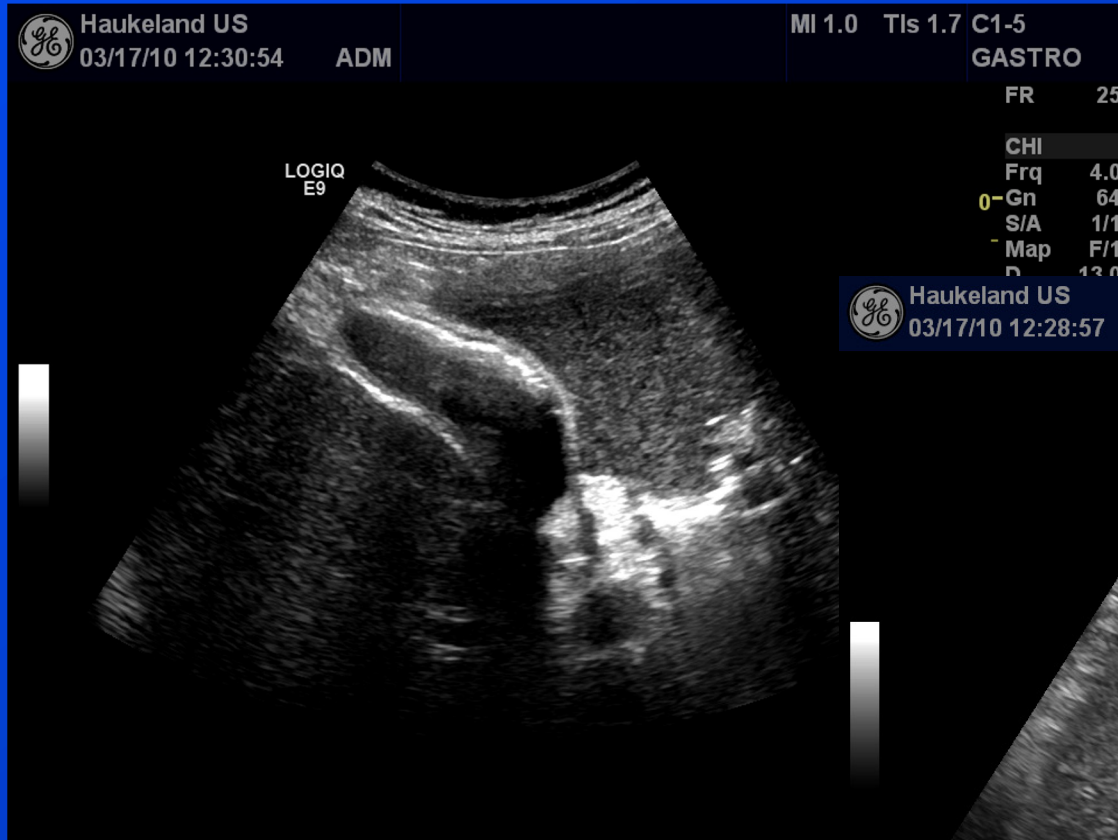


Gallbladder in Hepatitis





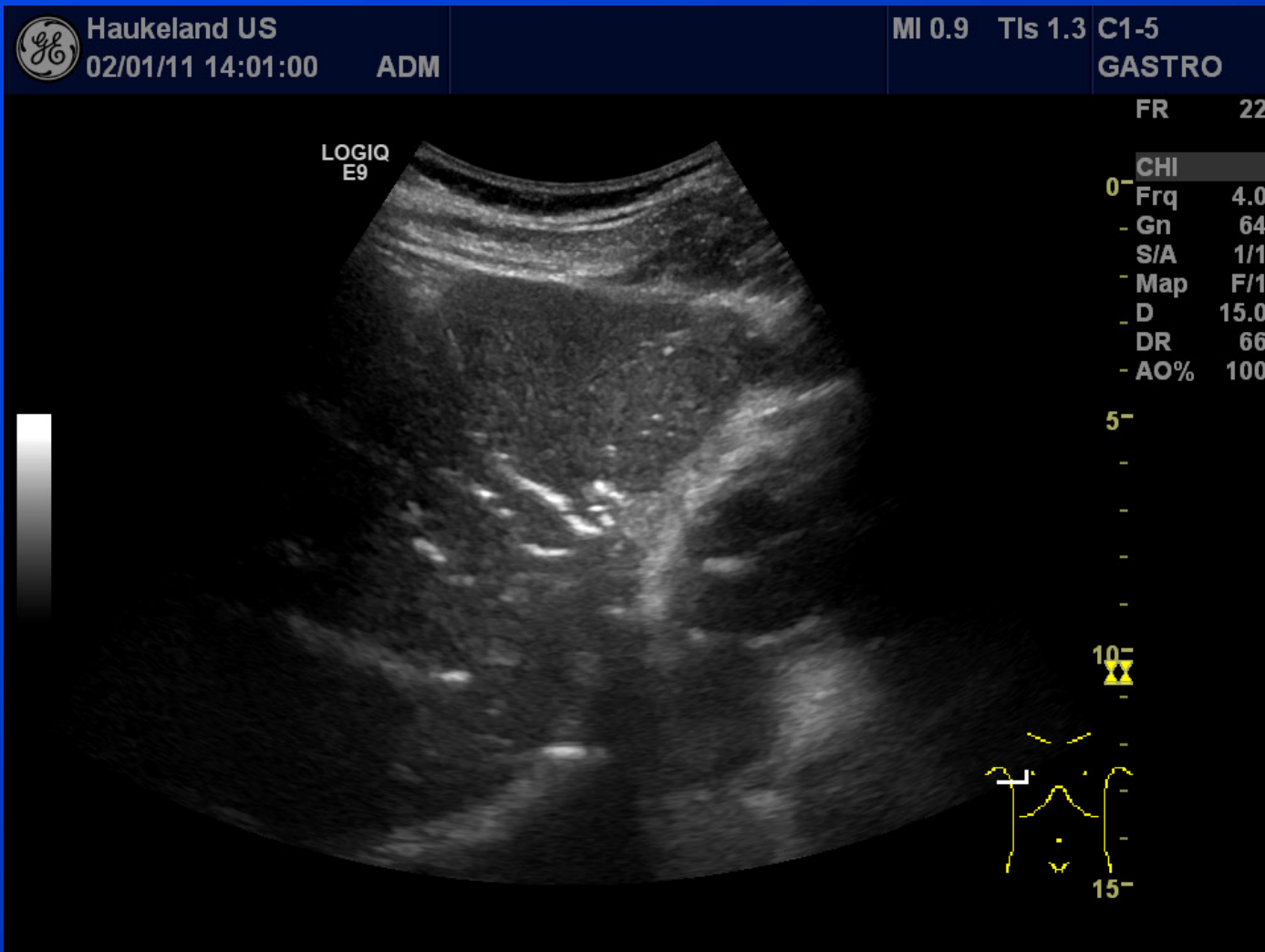
What is inside the Gallbladder?



Aerobilia



Aerobili



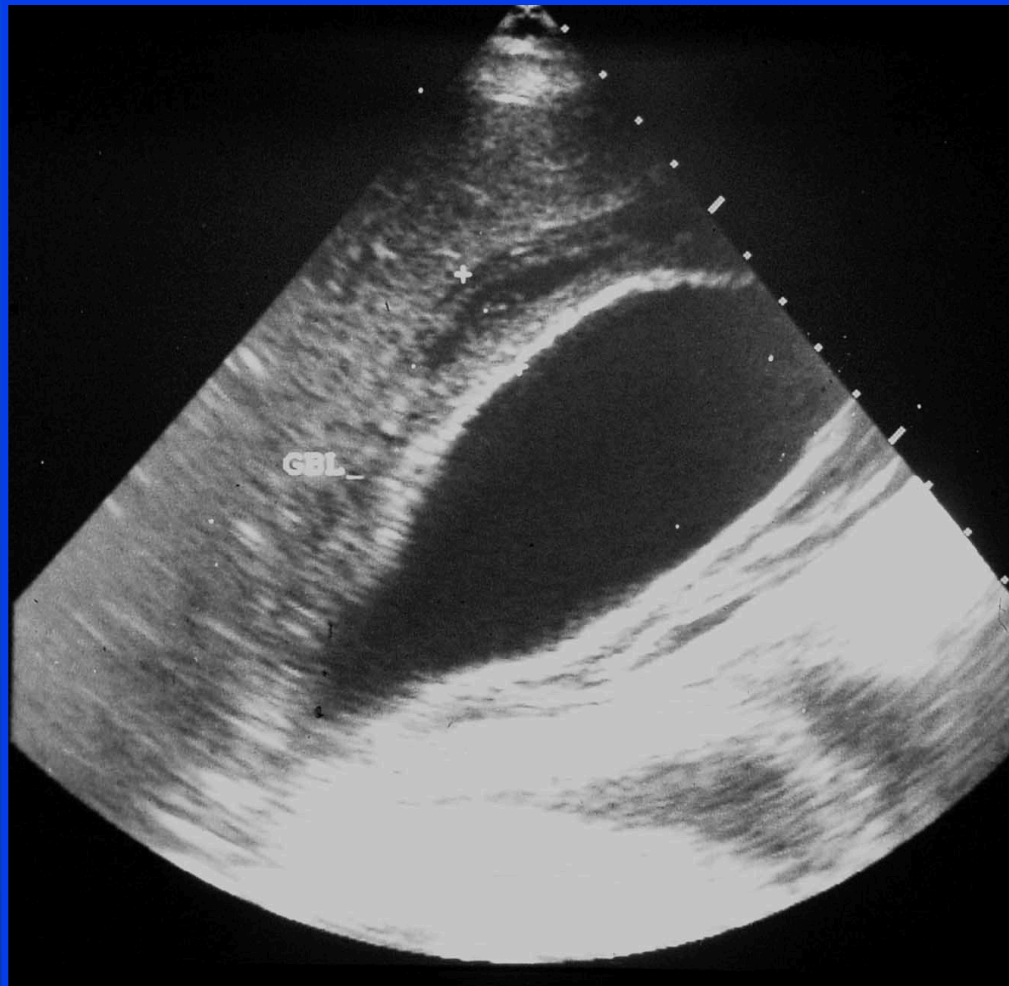


CHOLECYSTITIS

- Pain at "transducer-palpation"
- Wall thickness: 4 mm or more
- Cholecystolithiasis
- Dilated gallebladder: Diameter 4 cm or more
- Echopoor layer in the wall

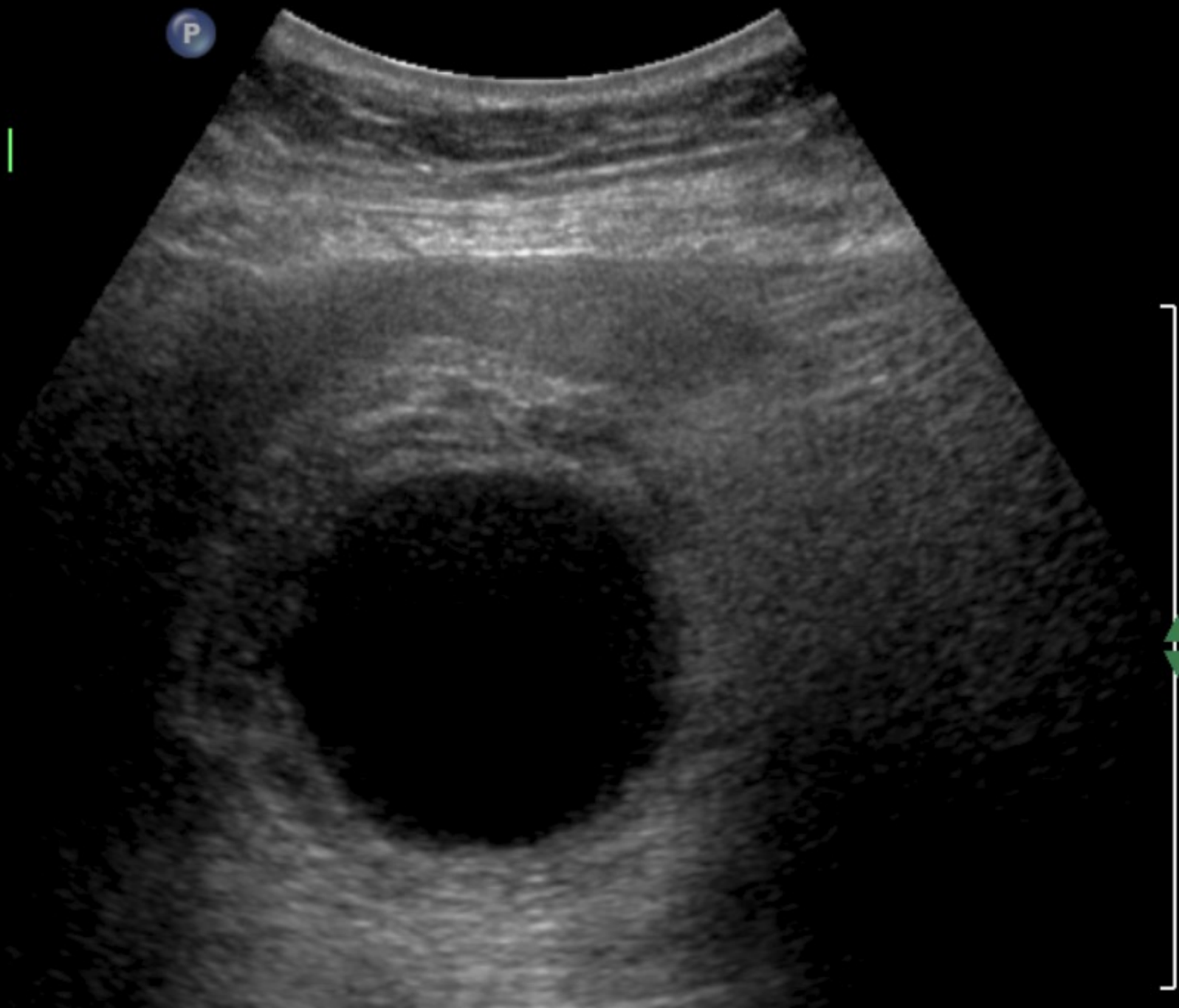

Cholecystitt



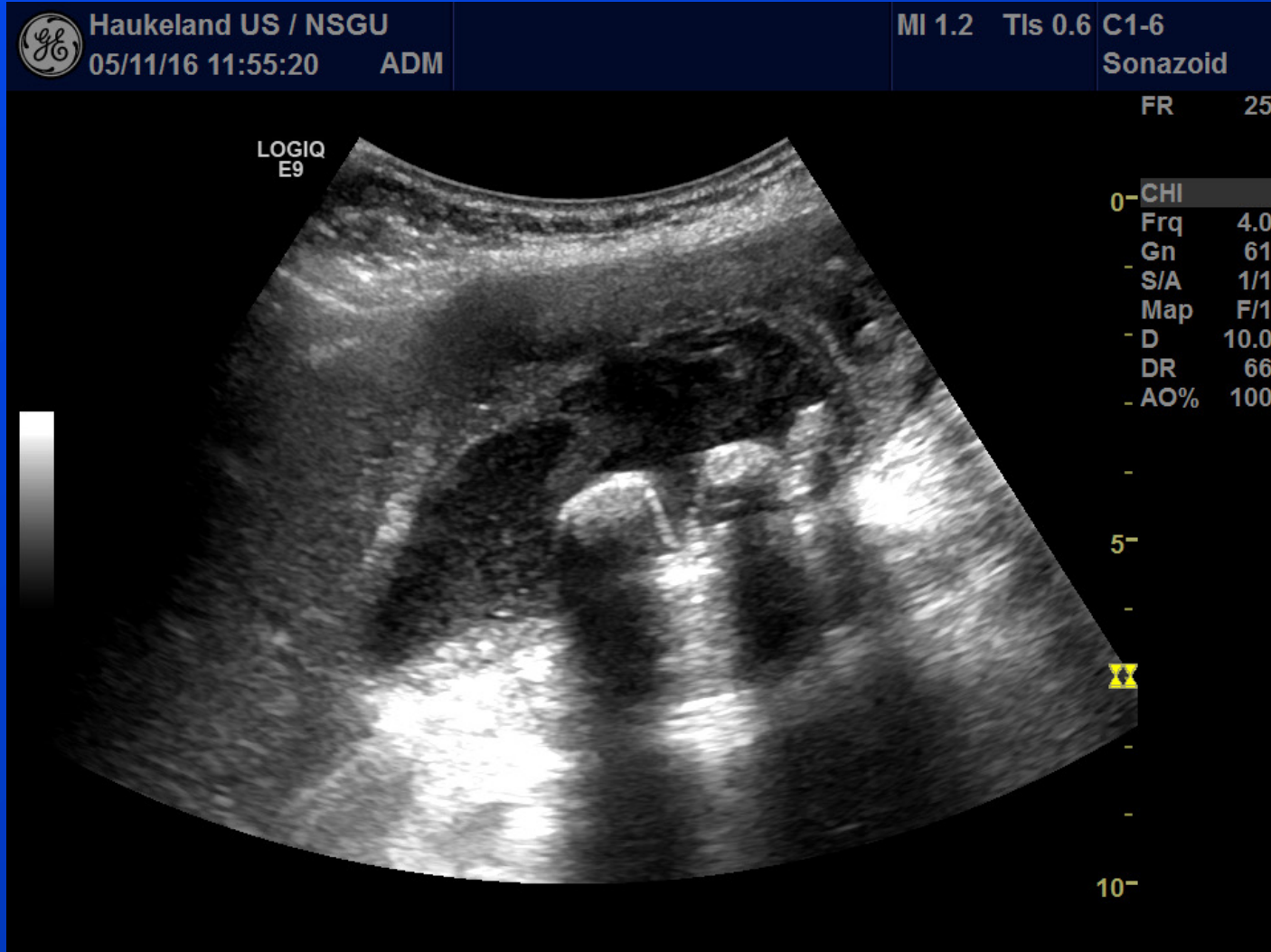P

GB





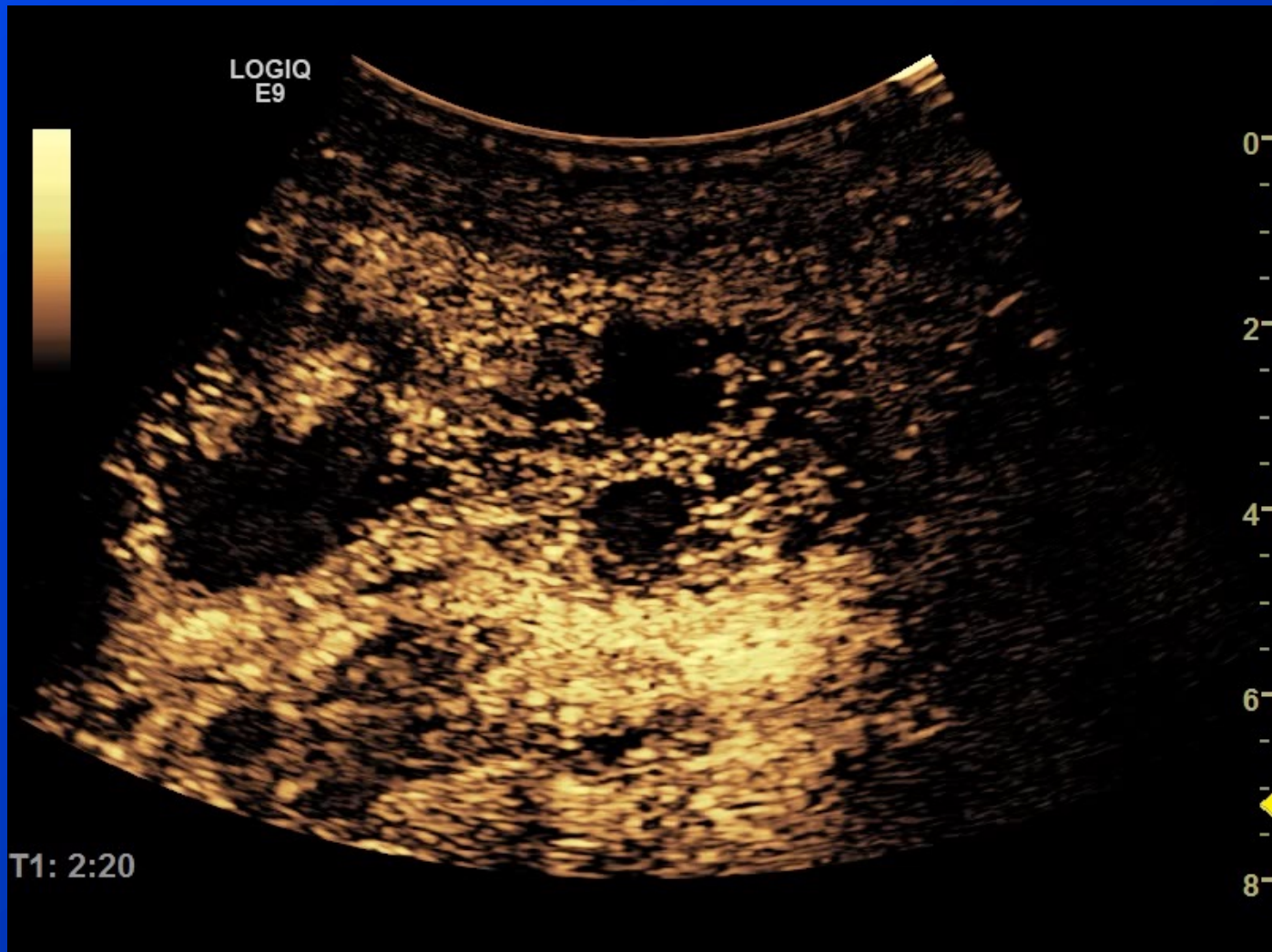
Complicated Cholecystitis





CEUS of gallbladder

Venous phase





Chronic Cholecystitis



Haukeland US
09/08/10 10:50:18

ADM

MI 1.2 TIs 1.6

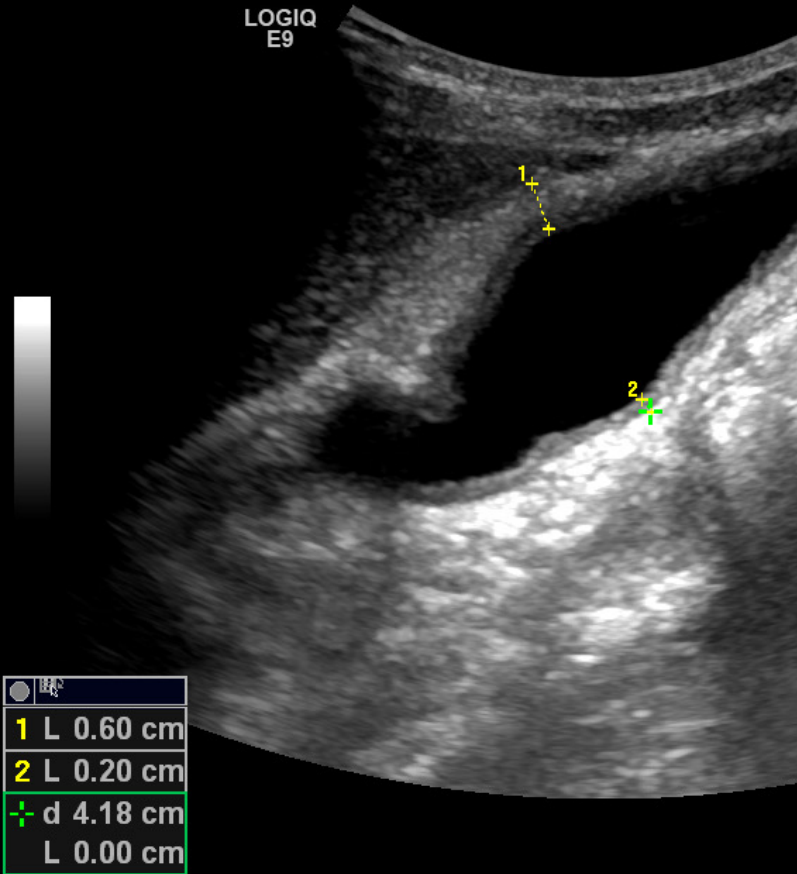
C1-5
GASTRO

FR 26

CHI

0- Frq 4.0
- Gn 64
- S/A 1/1
- Map F/1
D 9.0

LOGIQ
E9



| | | |
|-----|---|---------|
| 1 | L | 0.60 cm |
| 2 | L | 0.20 cm |
| + d | | 4.18 cm |
| L | | 0.00 cm |



Haukeland US
09/08/10 10:57:38

ADM

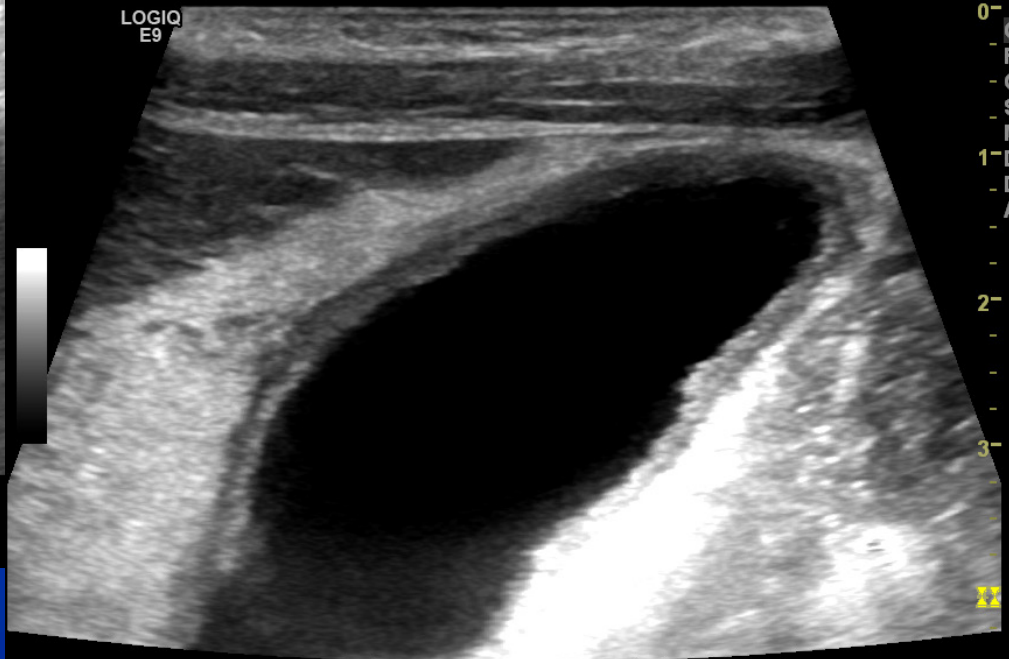
MI 1.2 TIs 0.8 9L

GASTRO

FR 34

0- CHI
- Frq 9.0
- Gn 53
- S/A 3/1
- Map F/1
1- D 4.5
- DR 63
- AO% 100

LOGIQ
E9





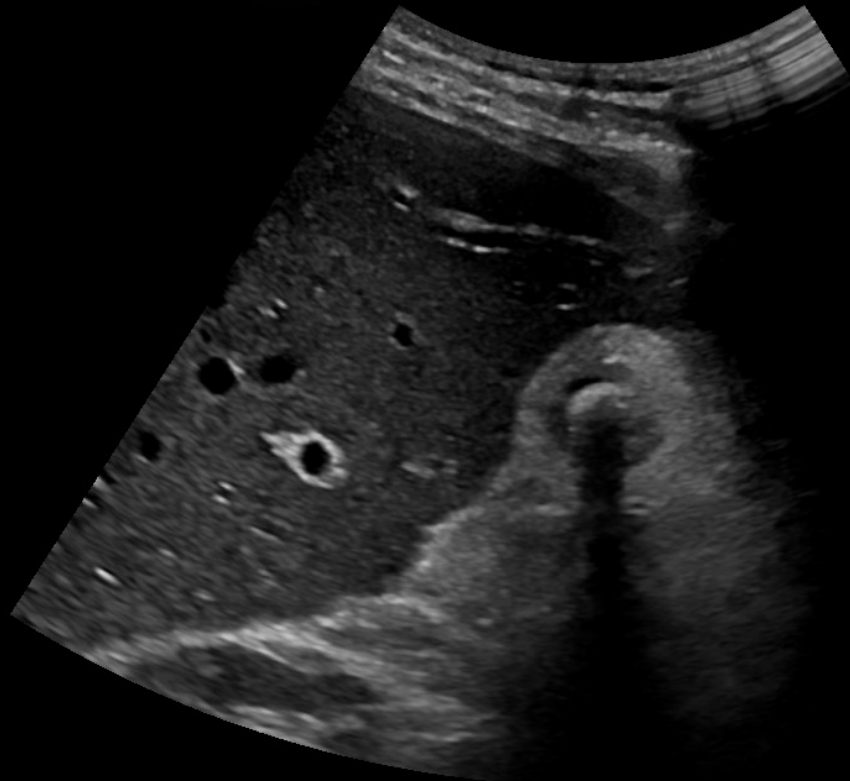Chronic cholecystitis



Haukeland
09/02/22 10:21:57

ADM

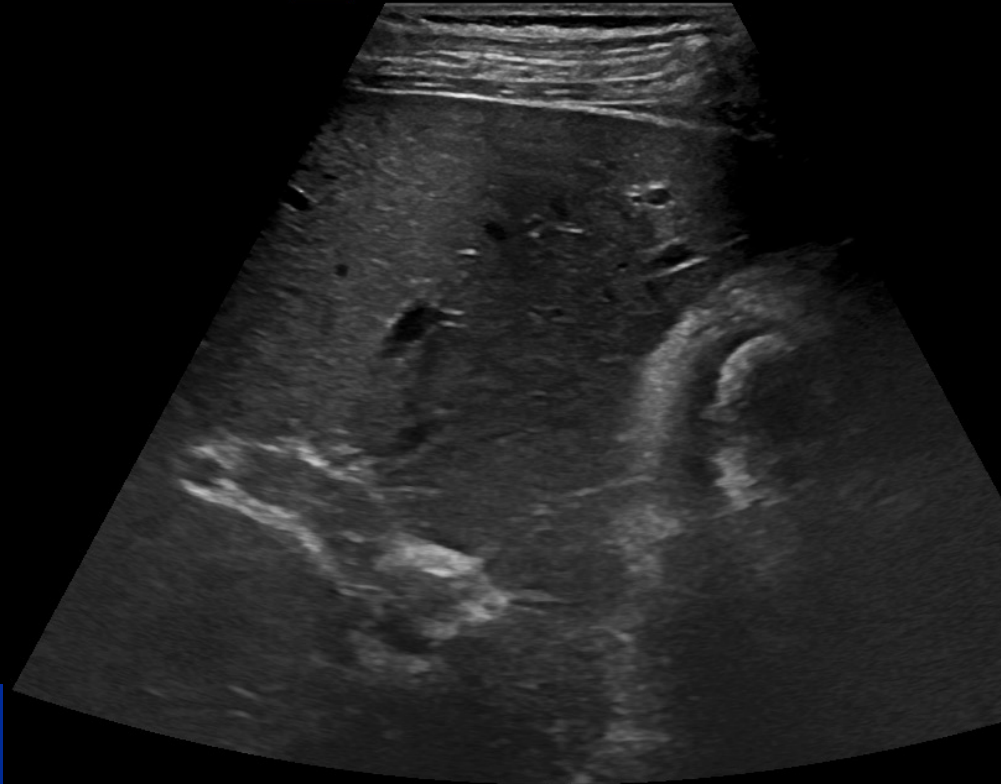
LOGIQ



Haukeland
09/02/22 10:38:20

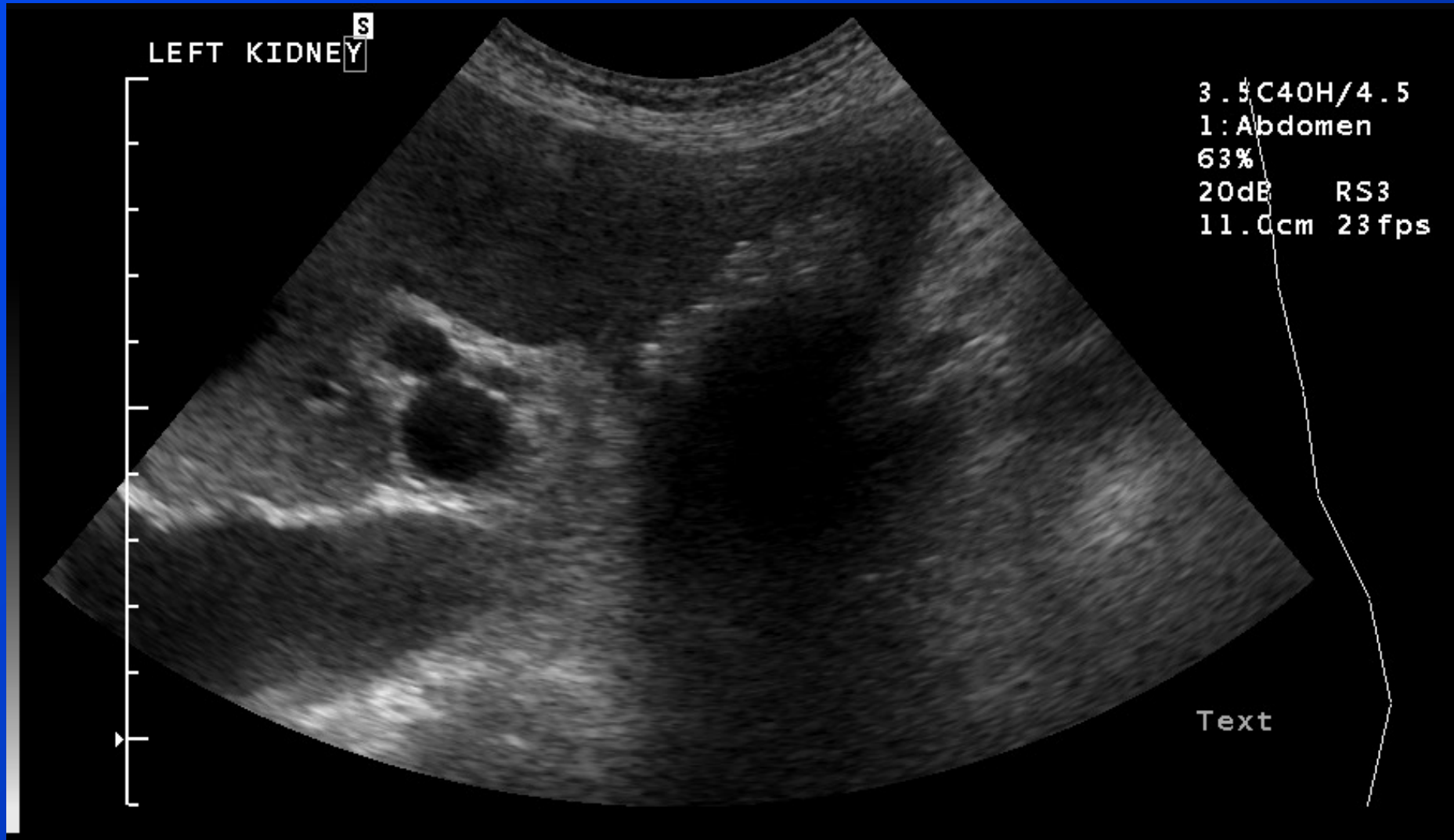
ADM

LOGIQ





Chronic Cholecystitis





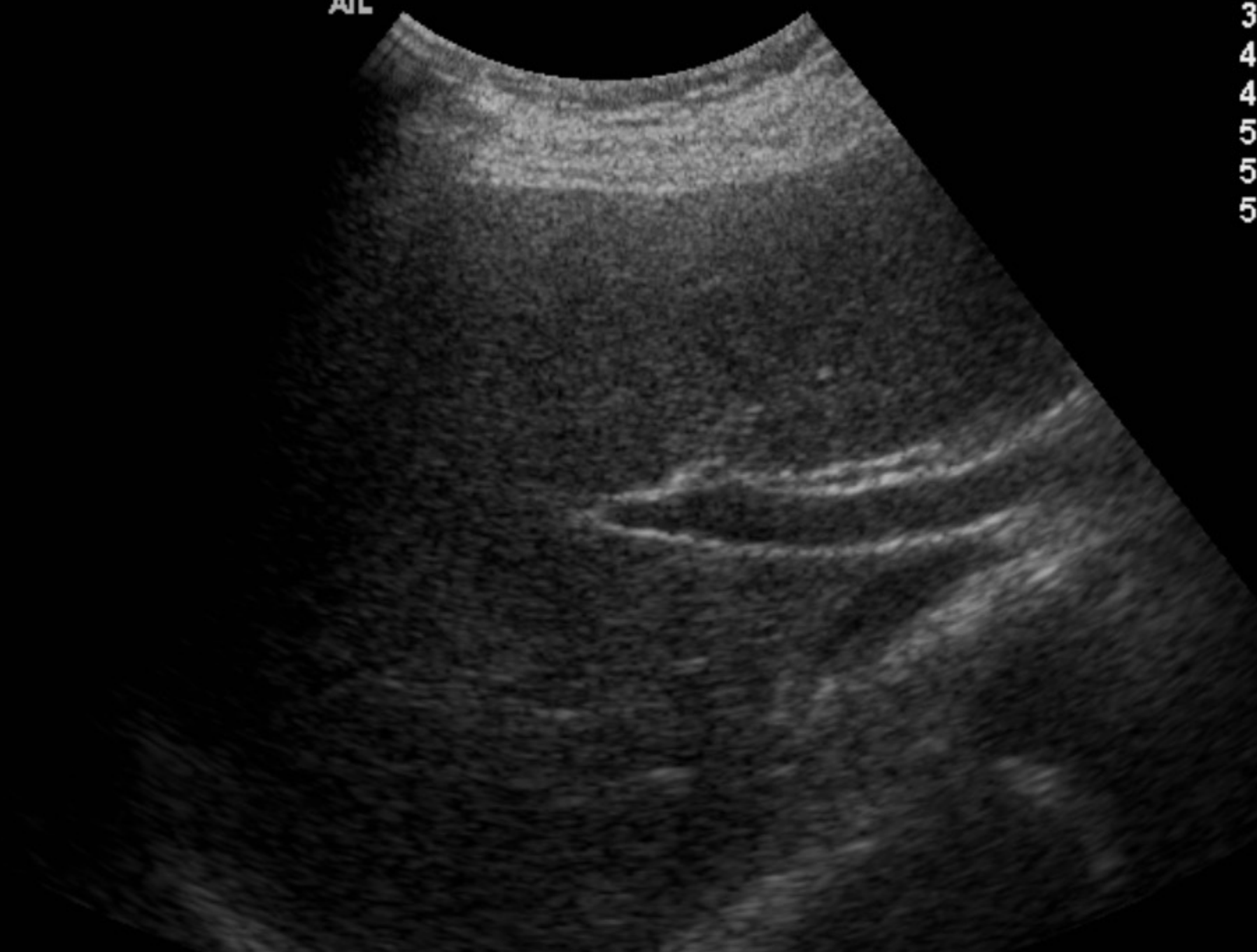
Bile duct caliper

- Intrahepatic bile ducts < 1-2 mm
- Ductus hepatis communis and ductus choledocus < 6 mm
- > 6 mm indicates obstruktion
- Increasing diameter with increasing age
- Increasing diameter after:
 - Postcholecystectomy
 - Post-ERCP with papillotomy

d
s
gh

ATL

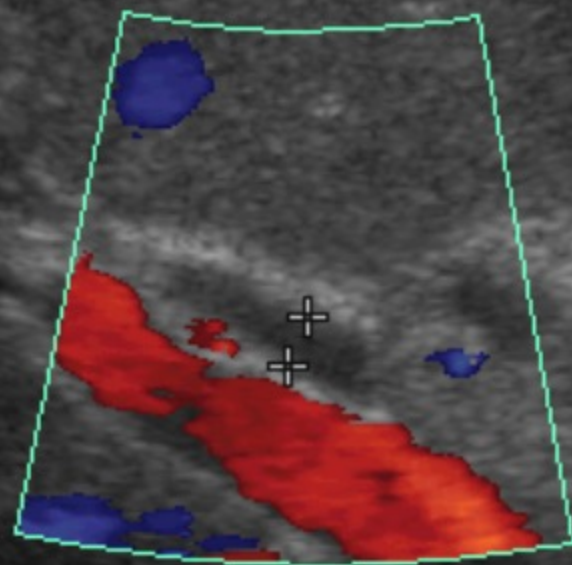
29
35
41
47
53
59
59



ATL

d
en
lap 5

Hz
Med V



56cm

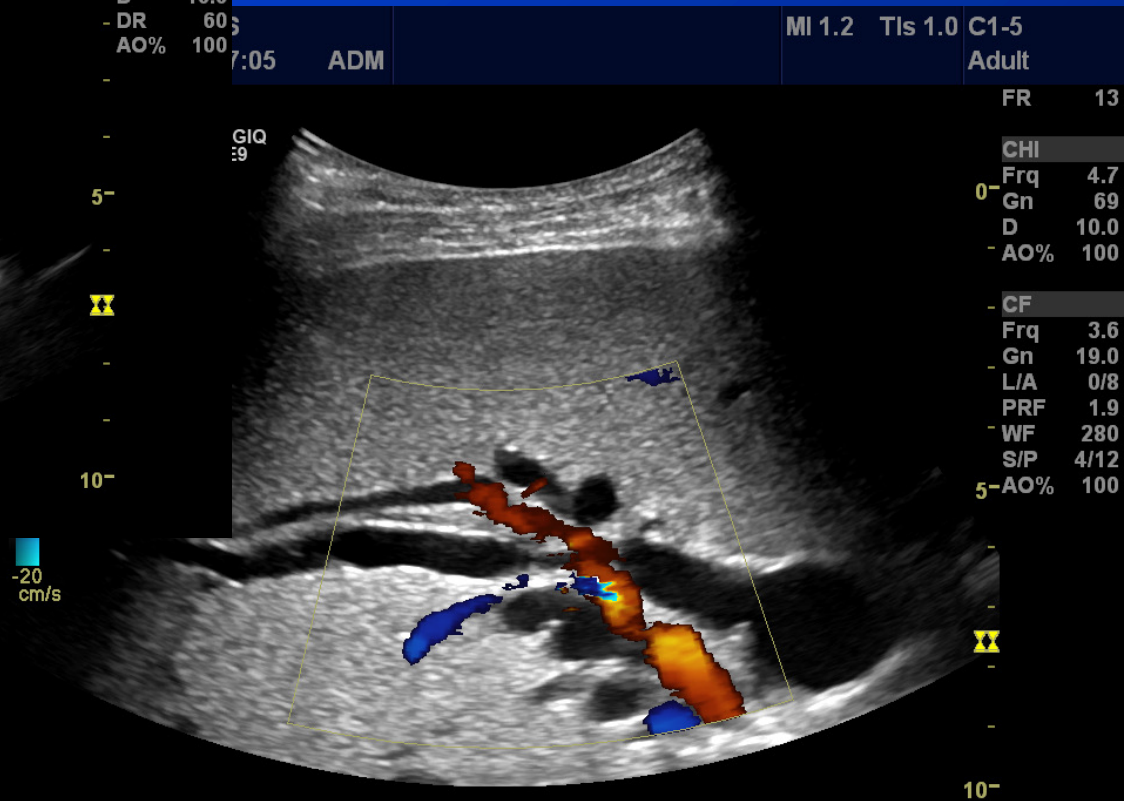
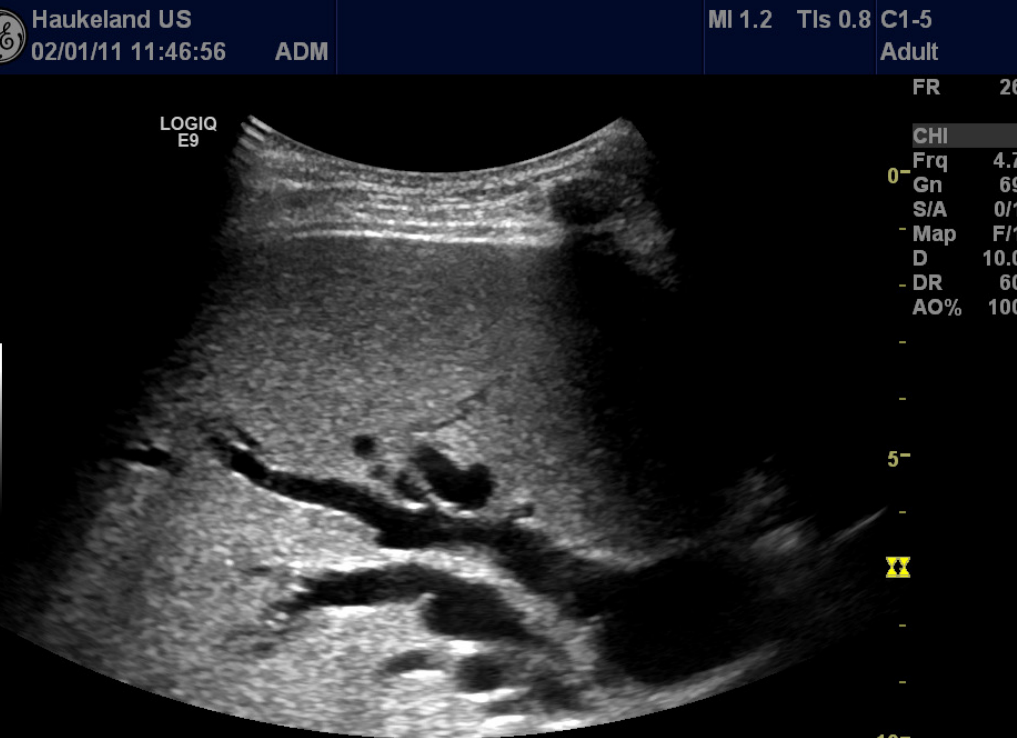

Causes of dilatation

- Stone
- Neoplasm
 - hepatocellular carcinoma
 - cholangiocarcinoma
 - metastasis
- Lymphadenopathy in the liver hilum
- Sclerosing cholangitis

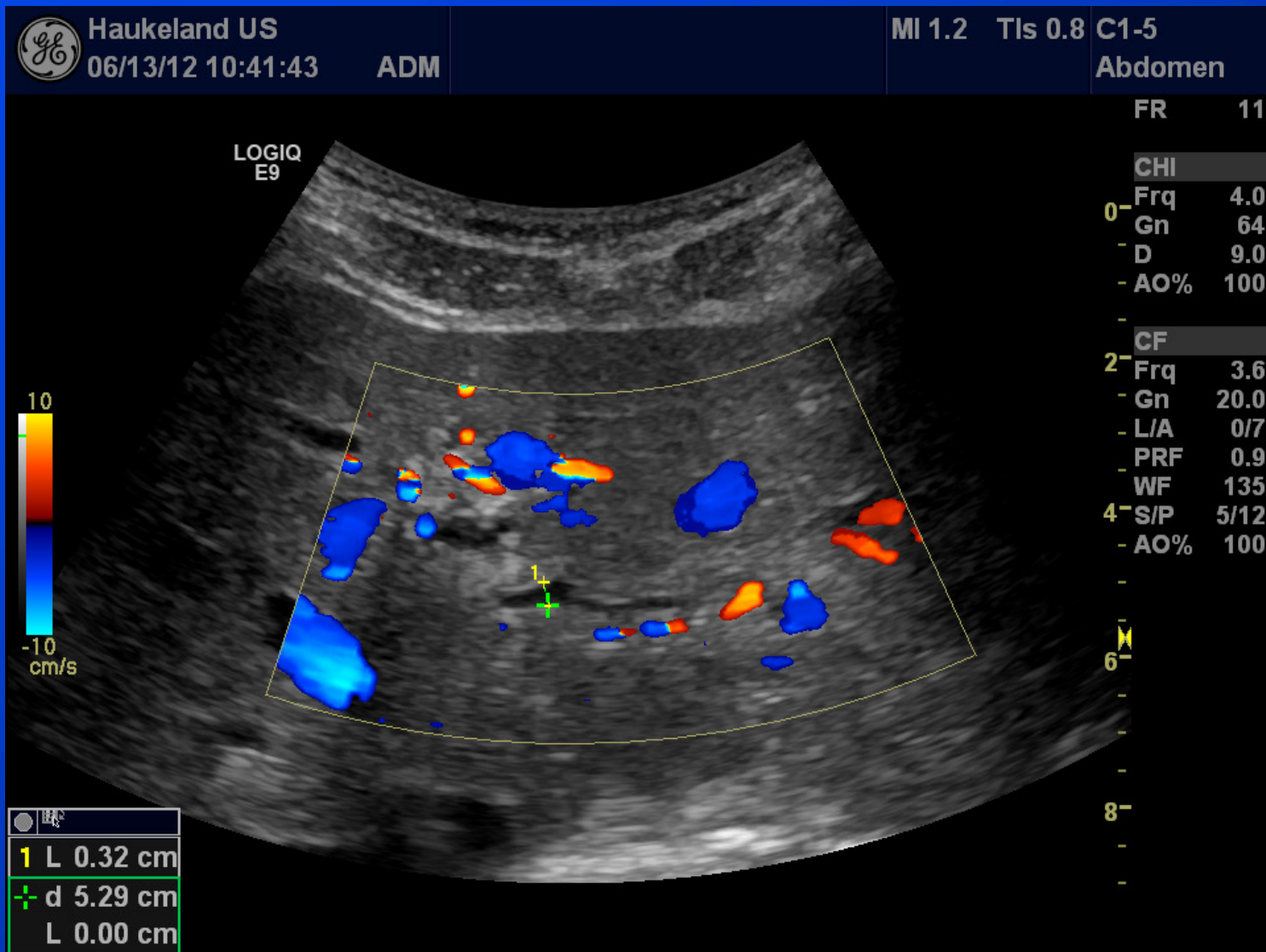


Intrahepatic Bile Duct Dilatation



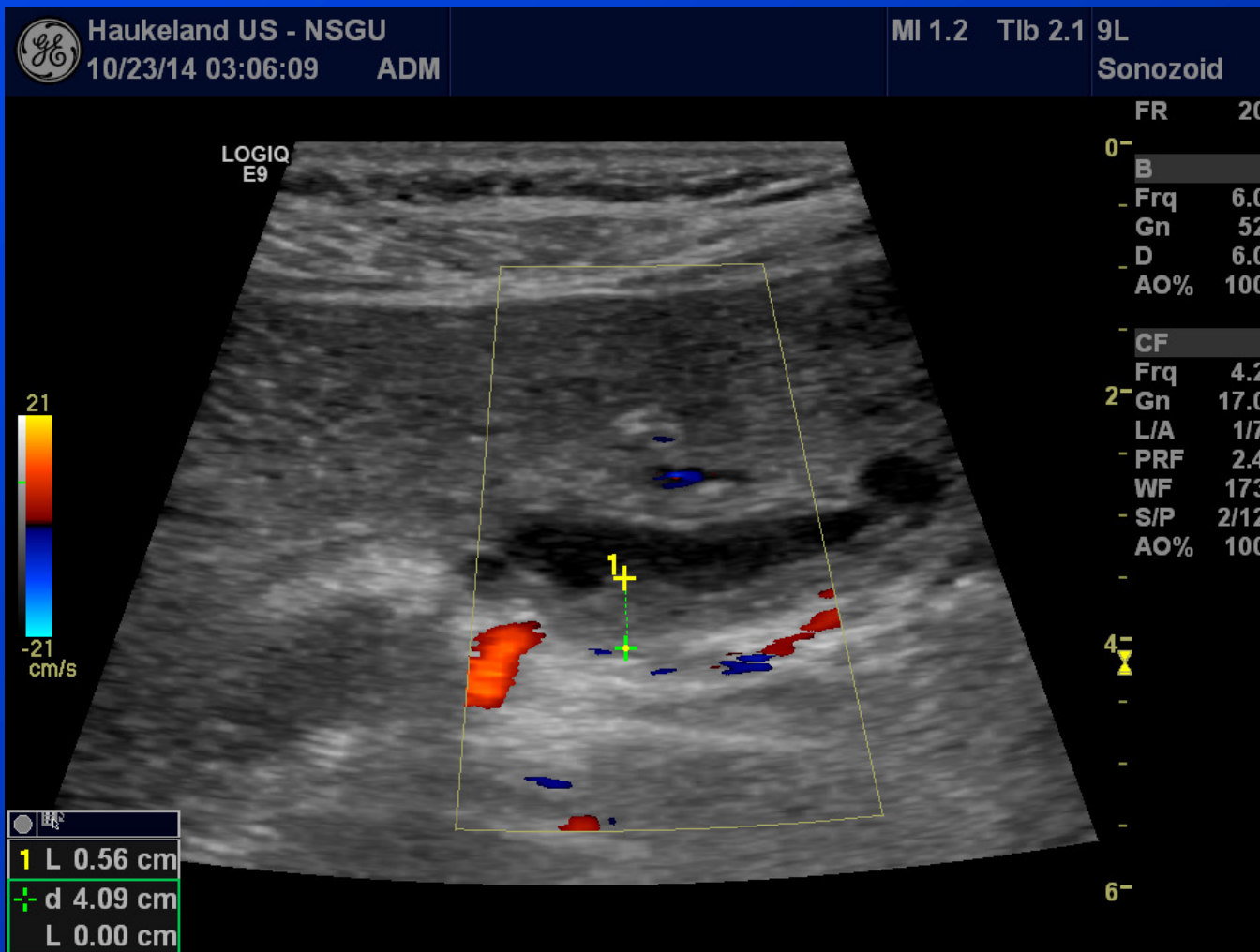


Ultrasound in PSC

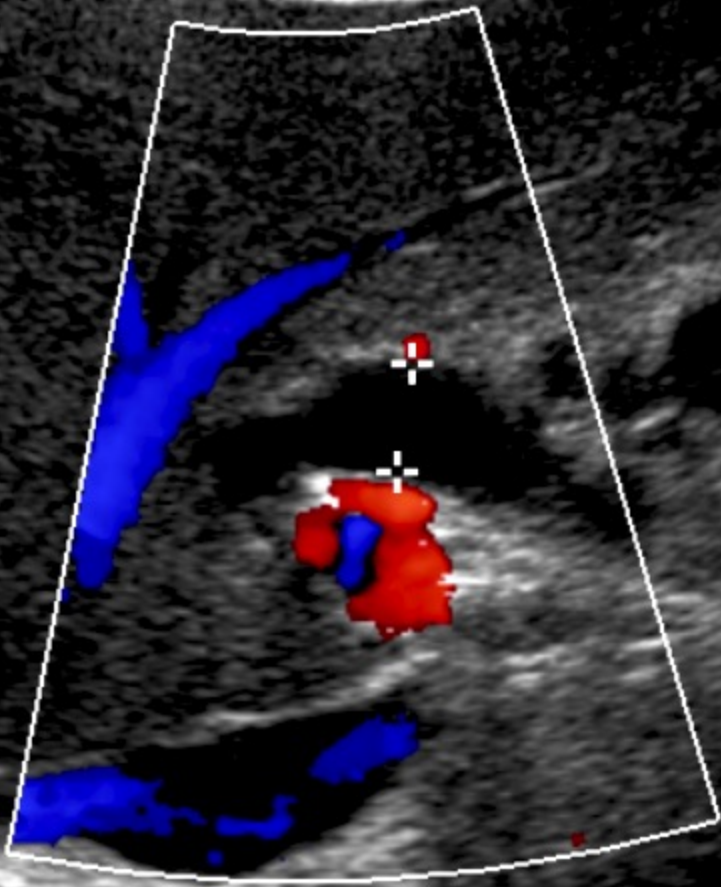
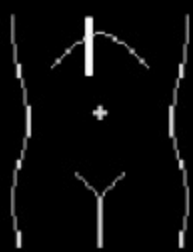



Intraductal growth: Inflammation or neoplasia ?

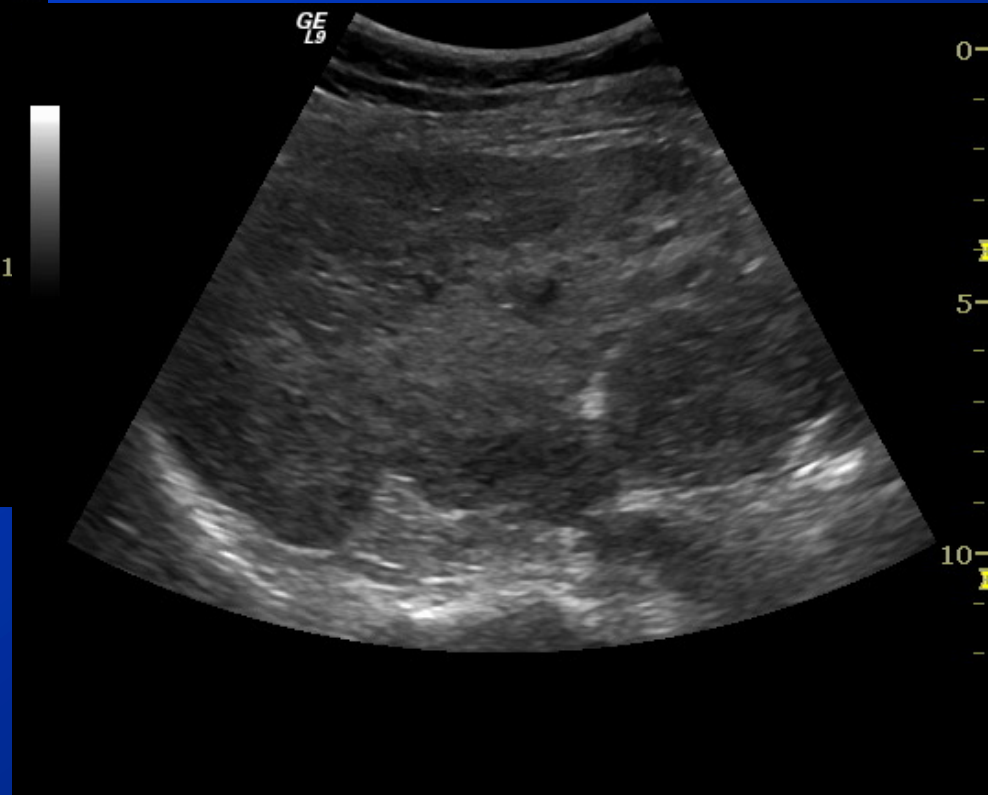
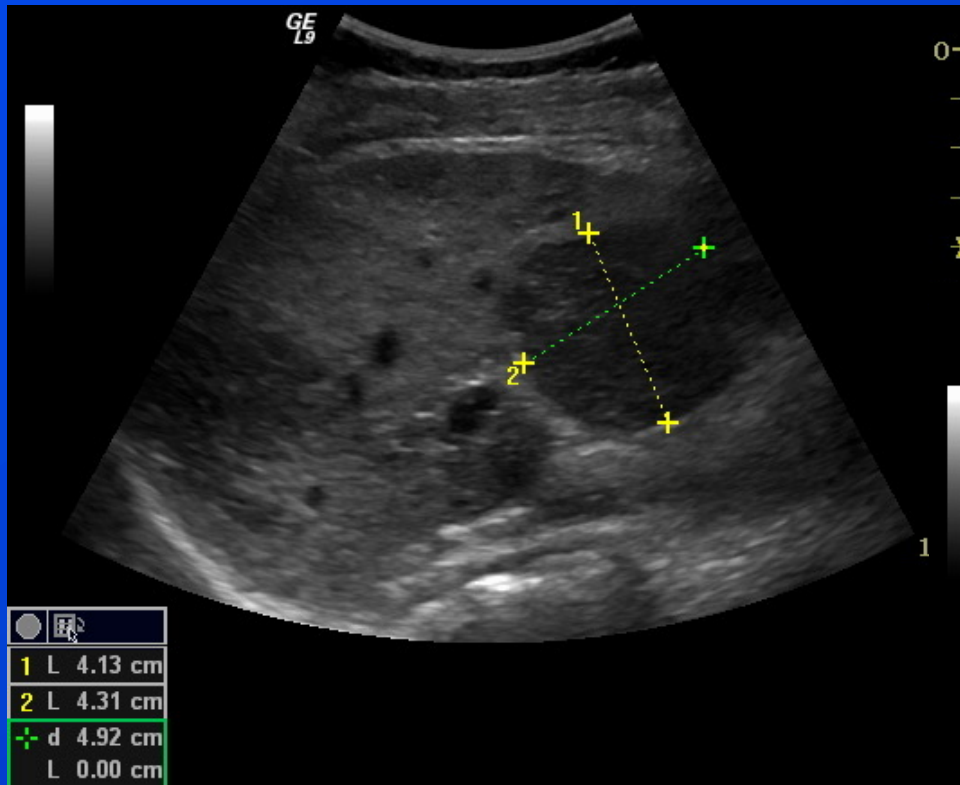


P



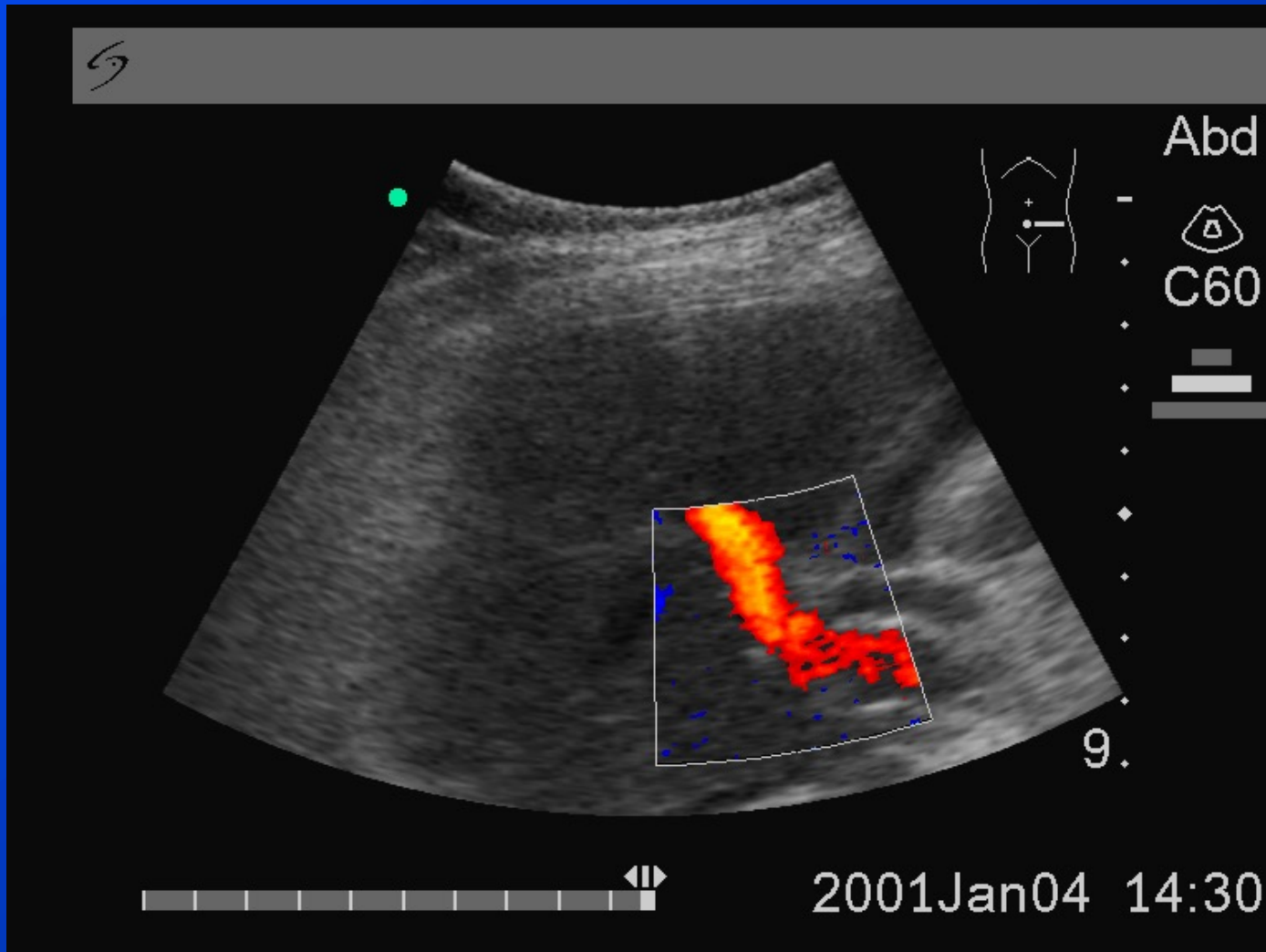


Intrahepatic Cholangiocarcinoma



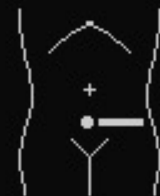

Female, 67 yrs. Silent jaundice





2.40cm



Abd

C60

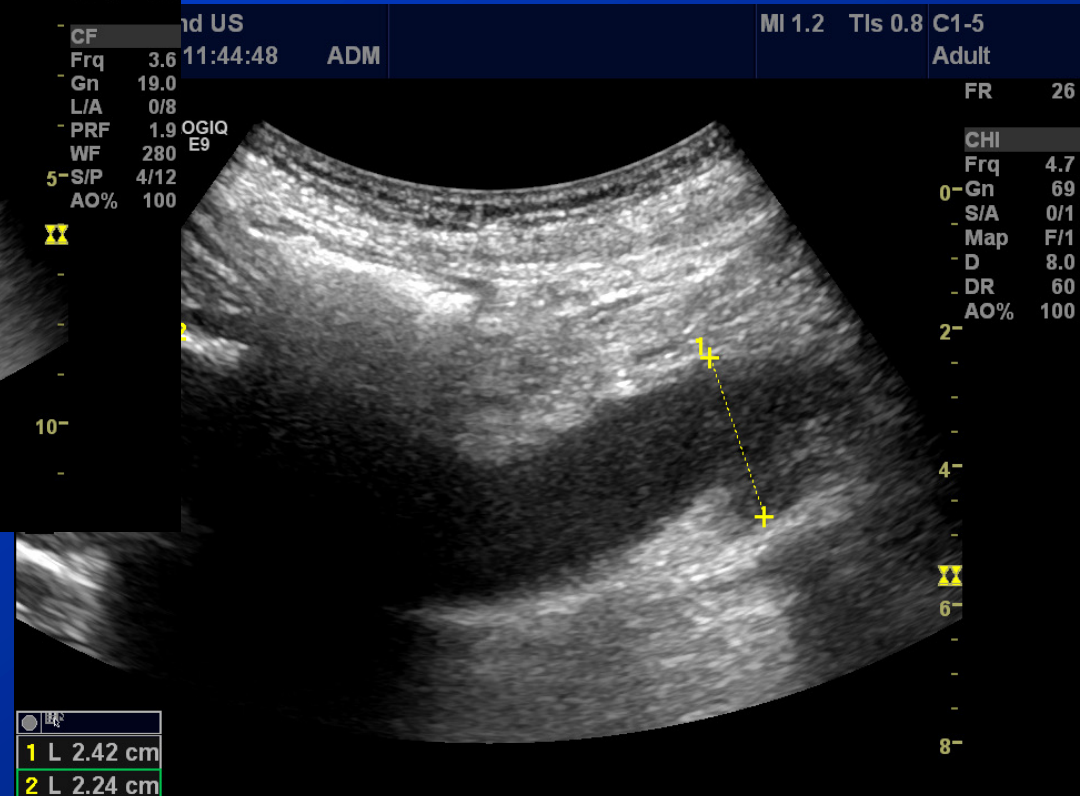
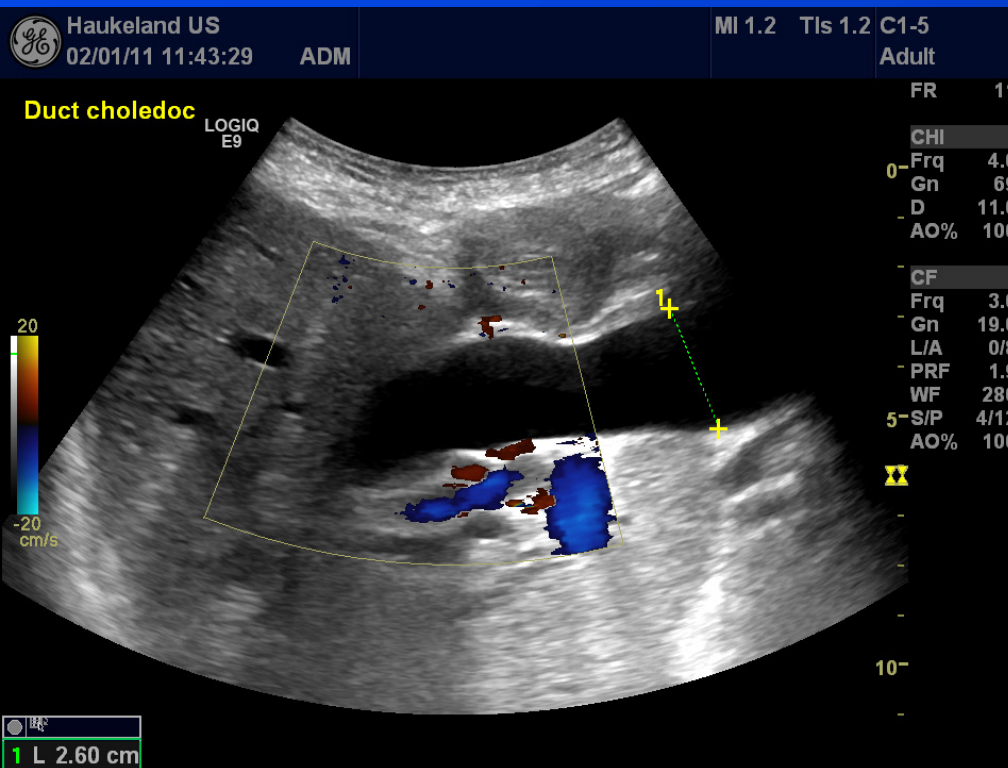


9.

2001Jan10 10:02

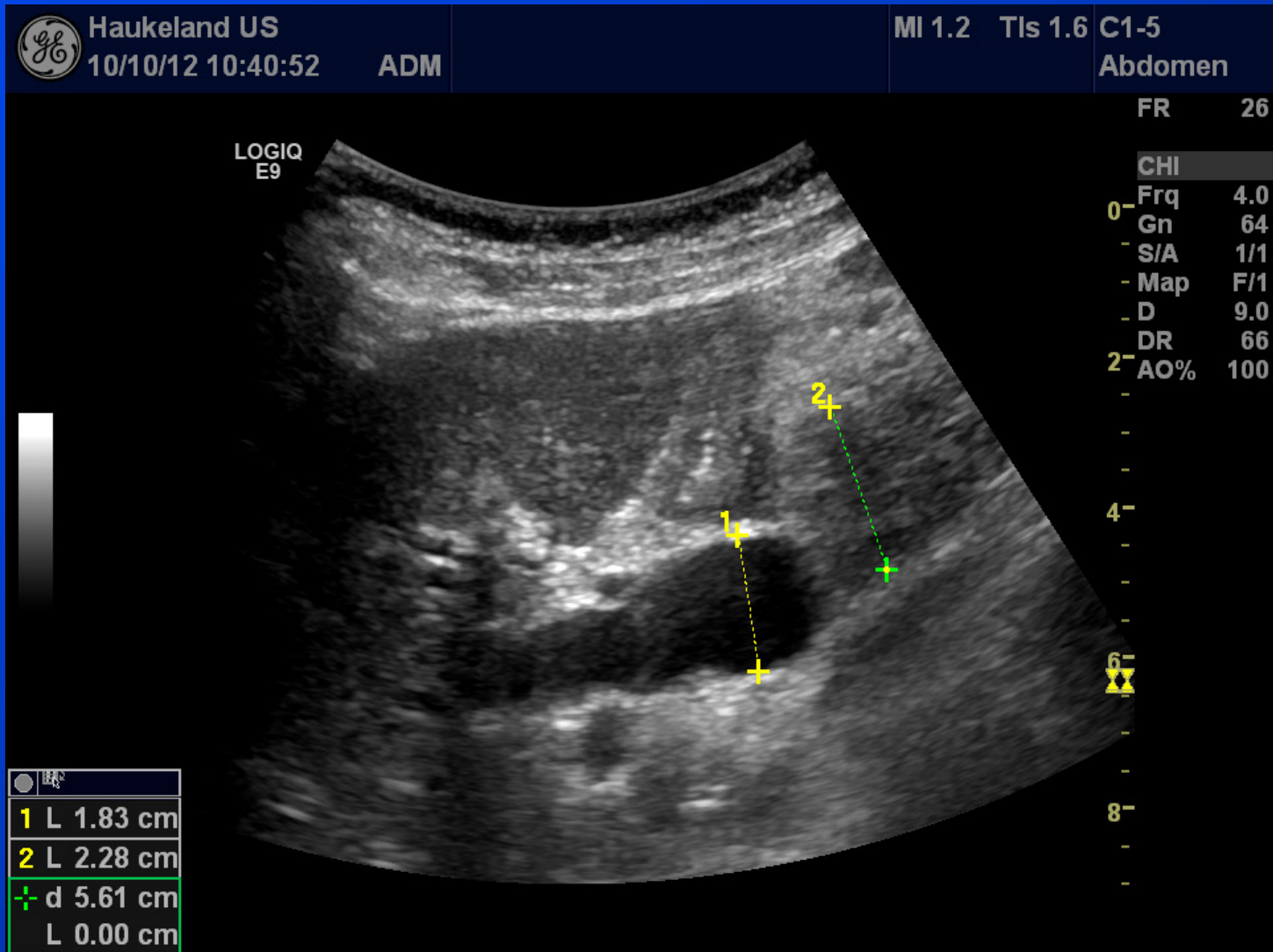


Dilated Common Bile Duct



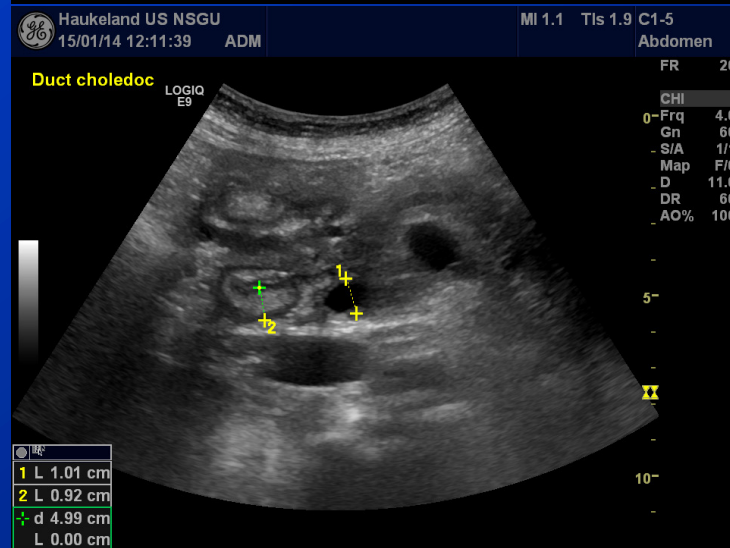
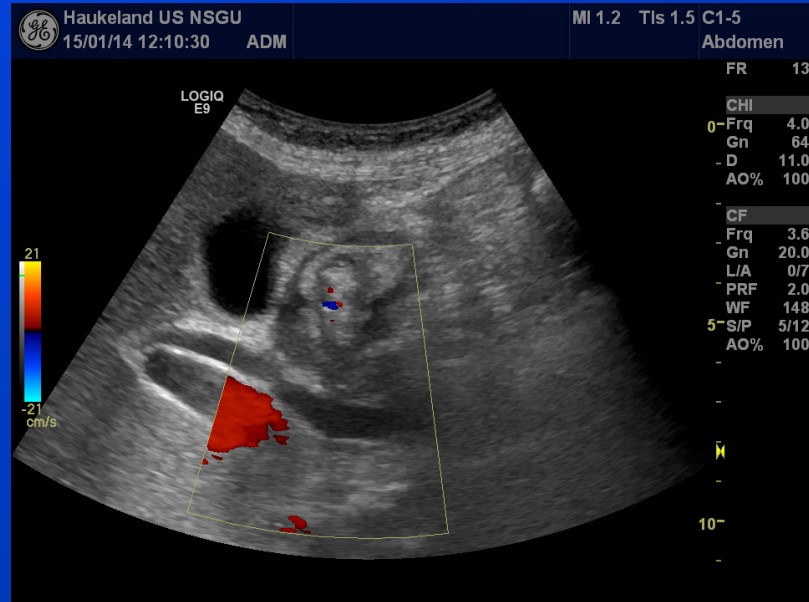
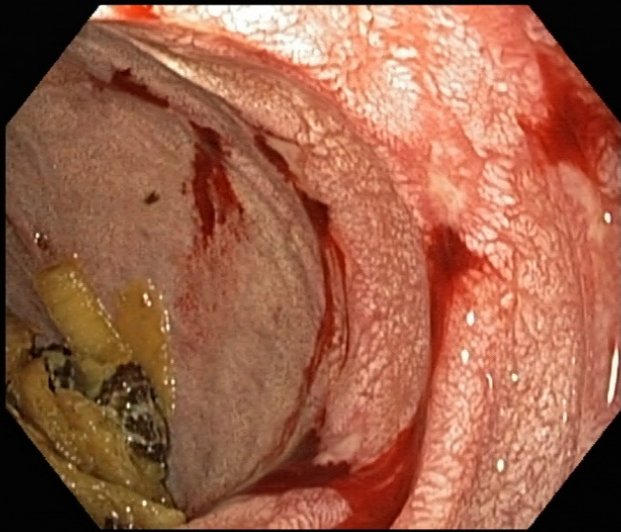
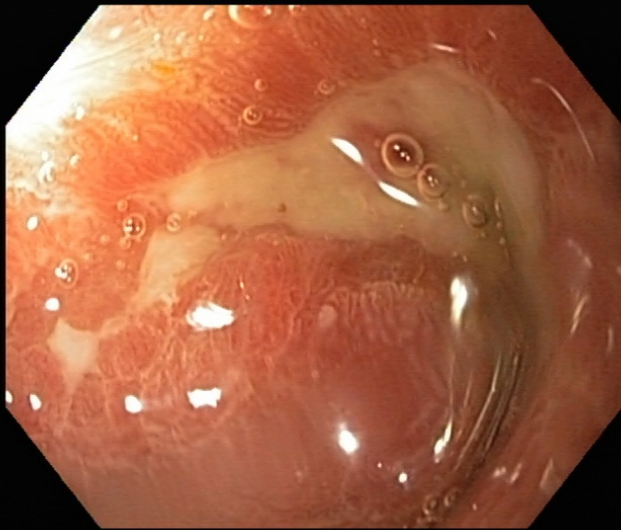


Extrahepatisk Bile Duct Dilatation





Crohn in the Duodenum





Conclusion

- Ultrasound is the method of choice to study diseases of the gallbladder
- Ultrasound can be used as a clinical tool
 - As a prolongation of the palpating hand
- Ultrasound can also be used to image biliary ducts, but MRCP and ERCP are the gold standards
- Malignancies of the gallbladder and biliary tract can be characterized by ultrasound



"Yes, we scan"





US first...



It's not FAKE news!



Biden ?





«Green Deal»



Ultrasound is “green”:

- No radiation
- Safe to repeat
- Low cost
- Widely available
- Short travel